

**MINISTRY OF HEALTHCARE OF UKRAINE  
HSEEU "Ukrainian Medical Stomatological Academy"**

**"Approved"**  
at the meeting of internal  
medicine №1 department  
Head of Department  
**Prof. Skrypyk I.M.**

---

Protocol № 4 from 13.10.2016

**GUIDELINES  
FOR STUDENTS  
INDEPENDENT WORK  
IN THE PRACTICAL CLASSES PREPARING**

<i>Academic discipline</i>	Internal medicine
<i>Module</i>	Current practice of internal medicine
<i>Content module</i>	Management of the patients with main symptoms and syndromes in rheumatology clinic
<i>Study subject</i>	<b>Management of the patients with purpura Management of patients with bleeding disorders</b>
<i>Course</i>	VI
<i>Faculty</i>	of foreign students training

## 1. The aims of the training course:

### To Know:

1. Differential diagnosis of hemorrhagic syndrome.
2. Potential mechanisms of vessel damage.
3. Pathogenic immune-complex formation complications.
4. Approach to a patient with suspected diagnosis of hemorrhagic syndrome.
5. Transfusion of blood components.
6. Primary and secondary prevention.
7. Weather and performance.

### To be able to:

- Conduct surveys and examination the patients with hemorrhagic syndrome.
- Justify the use of basic diagnostic methods, indications and contraindications for their conduction, possible complications.
- Identify typical and atypical clinical picture of major diseases and blood forming organs
- Draft examination of patients.
- Based on analysis of laboratory and instrumental examination to conduct differential diagnosis, justify and formulate diagnoses for hemorrhagic syndrome.
- Prescribe treatment, determine prognosis, to conduct primary and secondary prevention in major diseases and blood forming organs
- Diagnose and assist with hemorrhage due to diseases of blood and blood forming organs
- Identify blood transfuse blood components and blood substitutes

## 1. 2. Basic level training:

Previous Courses (Security discipline)	Received skills
Anatomy	Know the structure of vessels and circulatory system.
Pathophysiology	Identify the etiology and pathogenesis of systemic vasculitis
Propedeutics of Internal Medicine	Describe semiology systemic vasculitis, changes during the clinical examination of the patient, changes of laboratory and instrumental investigations.
Internal Medicine № 1, 2	Identify the typical clinical picture and the main diagnostic criteria for systemic vasculitis.
Next discipline	Department of Postgraduate Education

## 2. Track theme sessions

### Classification of systemic vasculitis

1. Vasculitis of small caliber vessels;
2. Vasculitis vascular caliber;
3. Vasculitis large caliber vessels.

### Note.

- For large caliber arteries are the aorta and its major branch, which are sent to major body parts (limbs, head, neck, etc.)
- For medium-sized arteries are the main visceral arteries (such as kidney, liver, coronary, mesenteric)
- For small caliber arteries: venules, capillaries, arterioles.

**Vasculitis** is a clinicopathologic process characterized by inflammation of and damage to blood vessels. The vessel lumen is usually compromised, and this is associated with ischemia of the tissues supplied by the involved vessel. A broad and heterogeneous group of syndromes may result from this process, since any type, size, and location of blood vessel may be involved. Vasculitis and its consequences may be the primary or sole manifestation of a disease; alternatively, vasculitis may be a secondary component of another primary disease. Vasculitis may be confined to a single organ, such as the skin, or it may simultaneously involve several organ systems.

### Classification

A major feature of the vasculitic syndromes as a group is the fact that there is a great deal of

heterogeneity at the same time as there is considerable overlap among them. This heterogeneity and overlap in addition to a lack of understanding of the pathogenesis of these syndromes have been major impediments to the development of a coherent classification system for these diseases. Table 1 lists the major vasculitis syndromes. The distinguishing and overlapping features of these syndromes are discussed below.

Table 1 Vasculitis Syndromes

Primary Vasculitis Syndromes	Secondary Vasculitis Syndromes
Granulomatosis with polyangiitis (Wegener's)	Drug-induced vasculitis
Churg-Strauss syndrome	Serum sickness
Polyarteritis nodosa	Vasculitis associated with other primary diseases
Microscopic polyangiitis	Infection
Giant cell arteritis	Malignancy
Takayasu's arteritis	Rheumatic disease
Henoch-Schönlein purpura	
Idiopathic cutaneous vasculitis	
Cryoglobulinemic vasculitis	
Behçet's syndrome	
Isolated vasculitis of the central nervous system	
Cogan's syndrome	
Kawasaki disease	

#### Pathophysiology and Pathogenesis

Generally, most of the vasculitic syndromes are assumed to be mediated at least in part by immunopathogenic mechanisms that occur in response to certain antigenic stimuli (Table 2). However, evidence supporting this hypothesis is for the most part indirect and may reflect epiphenomena as opposed to true causality. Furthermore, it is unknown why some individuals might develop vasculitis in response to certain antigenic stimuli, whereas others do not. It is likely that a number of factors are involved in the ultimate expression of a vasculitic syndrome. These include the genetic predisposition, environmental exposures, and the regulatory mechanisms associated with immune response to certain antigens.

Table 2 Potential Mechanisms of Vessel Damage in Vasculitis Syndromes

Pathogenic immune complex formation and/or deposition
Henoch-Schönlein purpura
Vasculitis associated with collagen vascular diseases
Serum sickness and cutaneous vasculitis syndromes
Hepatitis C-associated cryoglobulinemic vasculitis
Polyarteritis nodosa-like vasculitis associated with hepatitis B
Production of antineutrophilic cytoplasmic antibodies
Granulomatosis with polyangiitis (Wegener's)
Churg-Strauss syndrome
Microscopic polyangiitis
Pathogenic T lymphocyte responses and granuloma formation
Giant cell arteritis
Takayasu's arteritis
Granulomatosis with polyangiitis (Wegener's)
Churg-Strauss syndrome

#### Pathogenic Immune-Complex Formation

Vasculitis is generally considered within the broader category of *immune-complex diseases* that include serum sickness and certain of the connective tissue diseases, of which systemic lupus

erythematosis is the prototype. Although deposition of immune complexes in vessel walls is the most widely accepted pathogenic mechanism of vasculitis, the causal role of immune complexes has not been clearly established in most of the vasculitic syndromes. Circulating immune complexes need not result in deposition of the complexes in blood vessels with ensuing vasculitis, and many patients with active vasculitis do not have demonstrable circulating or deposited immune complexes. The actual antigen contained in the immune complex has only rarely been identified in vasculitic syndromes. In this regard, hepatitis B antigen has been identified in both the circulating and deposited immune complexes in a subset of patients who have features of a systemic vasculitis, most notably in polyarteritis nodosa (PAN). Cryoglobulinemic vasculitis is strongly associated with hepatitis C virus infection; hepatitis C virions and hepatitis C virus antigen-antibody complexes have been identified in the cryoprecipitates of these patients.

The mechanisms of tissue damage in immune complex-mediated vasculitis resemble those described for serum sickness. In this model, antigen-antibody complexes are formed in antigen excess and are deposited in vessel walls whose permeability has been increased by vasoactive amines such as histamine, bradykinin, and leukotrienes released from platelets or from mast cells as a result of IgE-triggered mechanisms. The deposition of complexes results in activation of complement components, particularly C5a, which is strongly chemotactic for neutrophils. These cells then infiltrate the vessel wall, phagocytose the immune complexes, and release their intracytoplasmic enzymes, which damage the vessel wall. As the process becomes subacute or chronic, mononuclear cells infiltrate the vessel wall. The common denominator of the resulting syndrome is compromise of the vessel lumen with ischemic changes in the tissues supplied by the involved vessel. Several variables may explain why only certain types of immune complexes cause vasculitis and why only certain vessels are affected in individual patients.

#### Antineutrophil Cytoplasmic Antibodies (ANCA)

ANCA are antibodies directed against certain proteins in the cytoplasmic granules of neutrophils and monocytes. These autoantibodies are present in a high percentage of patients with active granulomatosis with polyangiitis (Wegener's) and microscopic polyangiitis, and in a lower percentage of patients with Churg-Strauss syndrome. Because these diseases share the presence of ANCA and small-vessel vasculitis, some investigators have come to refer to them collectively as "ANCA-associated vasculitis." However, as these diseases possess unique clinical phenotypes in which ANCA may be absent, it remains our opinion that granulomatosis with polyangiitis (Wegener's), microscopic polyangiitis, and Churg-Strauss syndrome should continue to be viewed as separate entities.

There are two major categories of ANCA based on different targets for the antibodies. The terminology of *cytoplasmic ANCA* (cANCA) refers to the diffuse, granular cytoplasmic staining pattern observed by immunofluorescence microscopy when serum antibodies bind to indicator neutrophils. Proteinase-3, a 29-kDa neutral serine proteinase present in neutrophil azurophilic granules, is the major cANCA antigen. More than 90% of patients with typical active granulomatosis with polyangiitis (Wegener's) have detectable antibodies to proteinase-3 (see below). The terminology of *perinuclear ANCA* (pANCA) refers to the more localized perinuclear or nuclear staining pattern of the indicator neutrophils. The major target for pANCA is the enzyme myeloperoxidase; other targets that can produce a pANCA pattern of staining include elastase, cathepsin G, lactoferrin, lysozyme, and bactericidal/permeability-increasing protein. However, only antibodies to myeloperoxidase have been convincingly associated with vasculitis. Antimyeloperoxidase antibodies have been reported to occur in variable percentages of patients with microscopic polyangiitis, Churg-Strauss syndrome, crescentic glomerulonephritis, and granulomatosis with polyangiitis (Wegener's). A pANCA pattern of staining that is not due to antimyeloperoxidase antibodies has been associated with nonvasculitic entities such as rheumatic and nonrheumatic autoimmune diseases, inflammatory bowel disease, certain drugs, and infections such as endocarditis and bacterial airway infections in patients with cystic fibrosis.

It is unclear why patients with these vasculitis syndromes develop antibodies to myeloperoxidase or proteinase-3, whereas such antibodies are rare in other inflammatory diseases and autoimmune diseases. It is also unclear what role these antibodies play in disease pathogenesis.

### ***General Principles of Diagnosis***

The diagnosis of vasculitis is often considered in any patient with an unexplained systemic illness. However, there are certain clinical abnormalities that when present alone or in combination should suggest a diagnosis of vasculitis. These include palpable purpura, pulmonary infiltrates and microscopic hematuria, chronic inflammatory sinusitis, mononeuritis multiplex, unexplained ischemic events, and glomerulonephritis with evidence of multisystem disease. A number of nonvasculitic diseases may also produce some or all of these abnormalities. Thus, the first step in the workup of a patient with suspected vasculitis is to exclude other diseases that produce clinical manifestations that can mimic vasculitis (Table 3). It is particularly important to exclude infectious diseases with features that overlap those of vasculitis, especially if the patient's clinical condition is deteriorating rapidly and empirical immunosuppressive treatment is being contemplated.

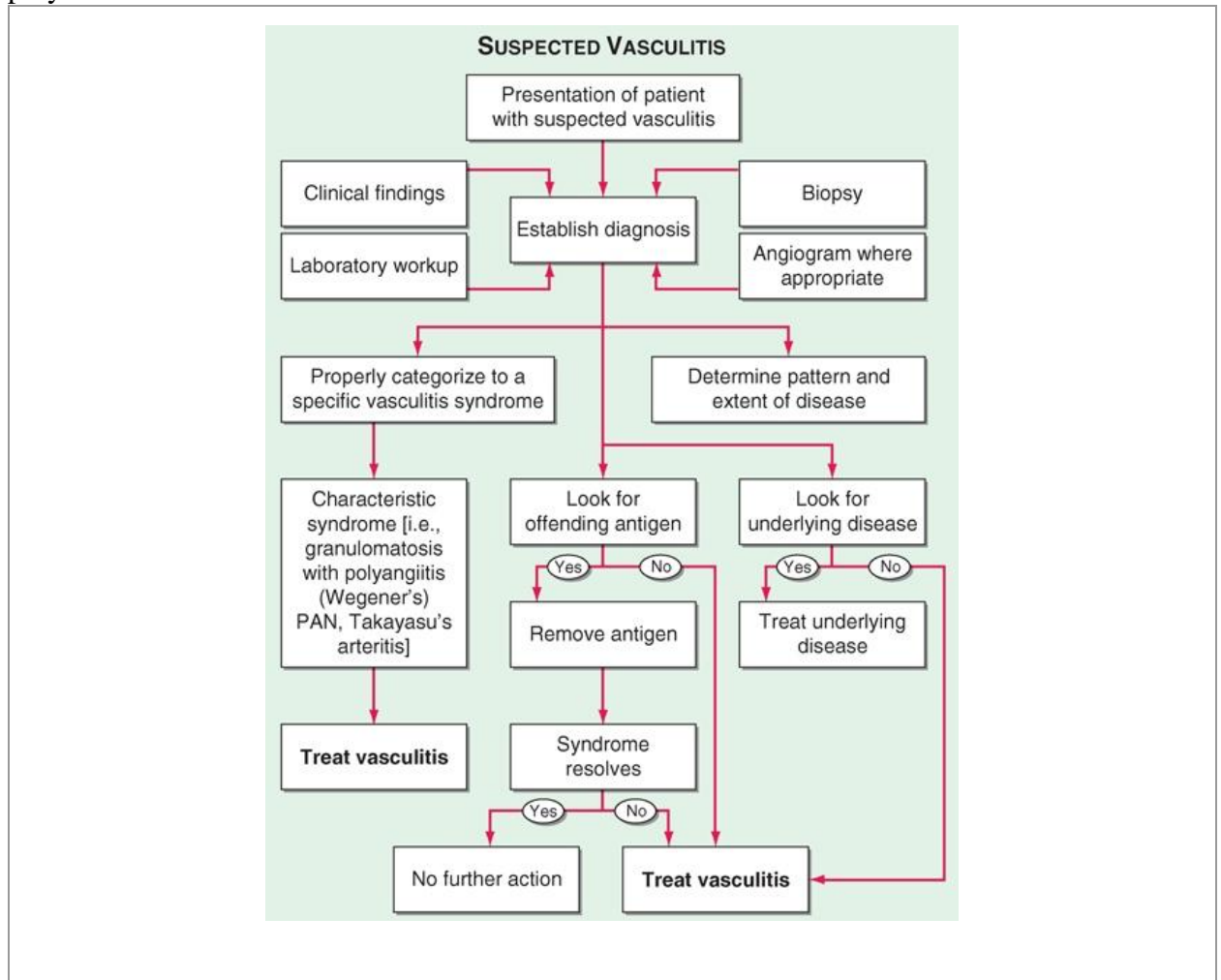
Table 3 Conditions that Can Mimic Vasculitis

Infectious diseases
Bacterial endocarditis
Disseminated gonococcal infection
Pulmonary histoplasmosis
Coccidioidomycosis
Syphilis
Lyme disease
Rocky Mountain spotted fever
Whipple's disease
Coagulopathies/thrombotic microangiopathies
Antiphospholipid antibody syndrome
Thrombotic thrombocytopenic purpura
Neoplasms
Atrial myxoma
Lymphoma
Carcinomatosis
Drug toxicity
Cocaine
Amphetamines
Ergot alkaloids
Methysergide
Arsenic
Sarcoidosis
Atheroembolic disease
Antiglomerular basement membrane disease (Goodpasture's syndrome)
Amyloidosis
Migraine

Once diseases that mimic vasculitis have been excluded, the workup should follow a series of progressive steps that establish the diagnosis of vasculitis and determine, where possible, the category of the vasculitis syndrome (Fig. 1). This approach is of considerable importance since several of the vasculitis syndromes require aggressive therapy with glucocorticoids and cytotoxic agents, while other syndromes usually resolve spontaneously and require symptomatic treatment only. The definitive diagnosis of vasculitis is made upon biopsy of involved tissue. The yield of "blind" biopsies of organs with no subjective or objective evidence of involvement is very low and should be avoided. When syndromes such as PAN, Takayasu's arteritis, or isolated central

nervous system (CNS) vasculitis are suspected, arteriogram of organs with suspected involvement should be performed. However, arteriograms should not be performed routinely when patients present with localized cutaneous vasculitis with no clinical indication of visceral involvement.

Figure 1. Algorithm for the approach to a patient with suspected diagnosis of vasculitis. PAN, polyarteritis nodosa.



### General Principles of Treatment

Once a diagnosis of vasculitis has been established, a decision regarding therapeutic strategy must be made (Fig. 1). If an offending antigen that precipitates the vasculitis is recognized, the antigen should be removed where possible. If the vasculitis is associated with an underlying disease such as an infection, neoplasm, or connective tissue disease, the underlying disease should be treated. If the syndrome represents a primary vasculitic disease, treatment should be initiated according to the category of the vasculitis syndrome. Specific therapeutic regimens are discussed below for the individual vasculitis syndromes; however, certain general principles regarding therapy should be considered. Decisions regarding treatment should be based upon the use of regimens for which there has been published literature supporting efficacy for that particular vasculitic disease. Since the potential toxic side effects of certain therapeutic regimens may be substantial, the risk-versus-benefit ratio of any therapeutic approach should be weighed carefully. On the one hand, glucocorticoids and/or cytotoxic therapy should be instituted immediately in diseases where irreversible organ system dysfunction and high morbidity and mortality rates have been clearly established. Granulomatosis with polyangiitis (Wegener's) is the prototype of a severe systemic vasculitis requiring such a therapeutic approach (see below). On the other hand, when feasible, aggressive therapy should be avoided for vasculitic manifestations that rarely result in irreversible organ system dysfunction and that usually do not respond to such therapy. For example, idiopathic cutaneous vasculitis usually resolves with

symptomatic treatment, and prolonged courses of glucocorticoids uncommonly result in clinical benefit. Cytotoxic agents have not proved to be beneficial in idiopathic cutaneous vasculitis, and their toxic side effects generally outweigh any potential beneficial effects. Glucocorticoids should be initiated in those systemic vasculitides that cannot be specifically categorized or for which there is no established standard therapy; cytotoxic therapy should be added in these diseases only if an adequate response does not result or if remission can only be achieved and maintained with an unacceptably toxic regimen of glucocorticoids. When remission is achieved, one should continually attempt to taper glucocorticoids and discontinue when possible. When using cytotoxic regimens, one should base the choice of agent upon the available therapeutic data supporting efficacy in that disease, the site and severity of organ involvement, and the toxicity profile of the drug.

### **Microscopic Polyangiitis**

The term *microscopic polyarteritis* was introduced into the literature by Davson in 1948 in recognition of the presence of glomerulonephritis in patients with PAN. In 1992, the Chapel Hill Consensus Conference on the Nomenclature of Systemic Vasculitis adopted the term *microscopic polyangiitis* to connote a necrotizing vasculitis with few or no immune complexes affecting small vessels (capillaries, venules, or arterioles). Glomerulonephritis is very common in microscopic polyangiitis, and pulmonary capillaritis often occurs. The absence of granulomatous inflammation in microscopic polyangiitis is said to differentiate it from granulomatosis with polyangiitis (Wegener's).

#### **Pathology and Pathogenesis**

The vasculitis seen in microscopic polyangiitis has a predilection to involve capillaries and venules in addition to small and medium-sized arteries. Immunohistochemical staining reveals a paucity of immunoglobulin deposition in the vascular lesion of microscopic polyangiitis, suggesting that immune-complex formation does not play a role in the pathogenesis of this syndrome. The renal lesion seen in microscopic polyangiitis is identical to that of granulomatosis with polyangiitis (Wegener's). Like granulomatosis with polyangiitis (Wegener's), microscopic polyangiitis is highly associated with the presence of ANCA, which may play a role in pathogenesis of this syndrome.

#### **Clinical and Laboratory Manifestations**

Because of its predilection to involve the small vessels, microscopic polyangiitis and granulomatosis with polyangiitis (Wegener's) share similar clinical features. Disease onset may be gradual, with initial symptoms of fever, weight loss, and musculoskeletal pain; however, it is often acute. Glomerulonephritis occurs in at least 79% of patients and can be rapidly progressive, leading to renal failure. Hemoptysis may be the first symptom of alveolar hemorrhage, which occurs in 12% of patients. Other manifestations include mononeuritis multiplex and gastrointestinal tract and cutaneous vasculitis. Upper airway disease and pulmonary nodules are not typically found in microscopic polyangiitis and, if present, suggest granulomatosis with polyangiitis (Wegener's).

Features of inflammation may be seen, including an elevated ESR, anemia, leukocytosis, and thrombocytosis. ANCA are present in 75% of patients with microscopic polyangiitis, with antineutrophil cytoplasmic antibodies being the predominant ANCA associated with this disease.

#### **Diagnosis**

The diagnosis is based on histologic evidence of vasculitis or pauci-immune glomerulonephritis in a patient with compatible clinical features of multisystem disease. Although microscopic polyangiitis is strongly ANCA-associated, no studies have as yet established the sensitivity and specificity of ANCA in this disease.

#### **Treatment: Microscopic Polyangiitis**

The 5-year survival rate for patients with treated microscopic polyangiitis is 74%, with disease-related mortality occurring from alveolar hemorrhage or gastrointestinal, cardiac, or renal disease. Studies on treatment have come from trials that have included patients with

granulomatosis with polyangiitis (Wegener's) or microscopic polyangiitis. Currently, the treatment approach for microscopic polyangiitis is the same as is used for granulomatosis with polyangiitis (Wegener's) for a detailed description of this therapeutic regimen), and patients with immediately life-threatening disease should be treated with the combination of prednisone and daily cyclophosphamide. Recent studies with rituximab also included ANCA positive patients with microscopic polyangiitis. Disease relapse has been observed in at least 34% of patients. Treatment for such relapses would be similar to that used at the time of initial presentation and based upon site and severity of disease.

### **Churg-Strauss Syndrome**

#### **Definition**

Churg-Strauss syndrome, also referred to as *allergic angiitis and granulomatosis*, was described in 1951 by Churg and Strauss and is characterized by asthma, peripheral and tissue eosinophilia, extravascular granuloma formation, and vasculitis of multiple organ systems.

#### **Pathology and Pathogenesis**

The necrotizing vasculitis of Churg-Strauss syndrome involves small and medium-sized muscular arteries, capillaries, veins, and venules. A characteristic histopathologic feature of Churg-Strauss syndrome is granulomatous reactions that may be present in the tissues or even within the walls of the vessels themselves. These are usually associated with infiltration of the tissues with eosinophils. This process can occur in any organ in the body; lung involvement is predominant, with skin, cardiovascular system, kidney, peripheral nervous system, and gastrointestinal tract also commonly involved. Although the precise pathogenesis of this disease is uncertain, its strong association with asthma and its clinicopathologic manifestations, including eosinophilia, granuloma, and vasculitis, point to aberrant immunologic phenomena.

#### **Clinical and Laboratory Manifestations**

Patients with Churg-Strauss syndrome often exhibit nonspecific manifestations such as fever, malaise, anorexia, and weight loss, which are characteristic of a multisystem disease. The pulmonary findings in Churg-Strauss syndrome clearly dominate the clinical picture with severe asthmatic attacks and the presence of pulmonary infiltrates. Mononeuritis multiplex is the second most common manifestation and occurs in up to 72% of patients. Allergic rhinitis and sinusitis develop in up to 61% of patients and are often observed early in the course of disease. Clinically recognizable heart disease occurs in 14% of patients and is an important cause of mortality. Skin lesions occur in 51% of patients and include purpura in addition to cutaneous and subcutaneous nodules. The renal disease in Churg-Strauss syndrome is less common and generally less severe than that of granulomatosis with polyangiitis (Wegener's) and microscopic polyangiitis.

The characteristic laboratory finding in virtually all patients with Churg-Strauss syndrome is a striking eosinophilia, which reaches levels  $>1000$  cells/ $\mu$ L in  $>80\%$  of patients. Evidence of inflammation as evidenced by elevated ESR, fibrinogen, or  $\alpha_2$ -globulins can be found in 81% of patients.

#### **Diagnosis**

Although the diagnosis of Churg-Strauss syndrome is optimally made by biopsy in a patient with the characteristic clinical manifestations, histologic confirmation can be challenging as the pathognomonic features often do not occur simultaneously. In order to be diagnosed with Churg-Strauss syndrome, a patient should have evidence of asthma, peripheral blood eosinophilia, and clinical features consistent with vasculitis.

#### **Treatment: Churg-Strauss Syndrome**

Glucocorticoids alone appear to be effective in many patients. Dosage tapering is often limited by asthma, and many patients require low-dose prednisone for persistent asthma many years after clinical recovery from vasculitis. In glucocorticoid failure or in patients who present with fulminant multisystem disease, the treatment of choice is a combined regimen of daily cyclophosphamide and prednisone (see "Granulomatosis With Polyangiitis (Wegener's)" for a detailed description of this therapeutic regimen).

### **Polyarteritis Nodosa**



## Definition

PAN, also referred to as *classic PAN*, was described in 1866 by Kussmaul and Maier. It is a multisystem, necrotizing vasculitis of small and medium-sized muscular arteries in which involvement of the renal and visceral arteries is characteristic. PAN does not involve pulmonary arteries, although bronchial vessels may be involved; granulomas, significant eosinophilia, and an allergic diathesis are not observed.

## Pathology and Pathogenesis

The vascular lesion in PAN is a necrotizing inflammation of small and medium-sized muscular arteries. The lesions are segmental and tend to involve bifurcations and branchings of arteries. They may spread circumferentially to involve adjacent veins. However, involvement of venules is not seen in PAN and, if present, suggests microscopic polyangiitis (see below). In the acute stages of disease, polymorphonuclear neutrophils infiltrate all layers of the vessel wall and perivascular areas, which results in intimal proliferation and degeneration of the vessel wall. Mononuclear cells infiltrate the area as the lesions progress to the subacute and chronic stages. Fibrinoid necrosis of the vessels ensues with compromise of the lumen, thrombosis, infarction of the tissues supplied by the involved vessel, and, in some cases, hemorrhage. As the lesions heal, there is collagen deposition, which may lead to further occlusion of the vessel lumen.

Aneurysmal dilations up to 1 cm in size along the involved arteries are characteristic of PAN.

Granulomas and substantial eosinophilia with eosinophilic tissue infiltrations are not characteristically found and suggest Churg-Strauss syndrome.

Multiple organ systems are involved, and the clinicopathologic findings reflect the degree and location of vessel involvement and the resulting ischemic changes. As mentioned above, pulmonary arteries are not involved in PAN, and bronchial artery involvement is uncommon. The pathology in the kidney in classic PAN is that of arteritis without glomerulonephritis. In patients with significant hypertension, typical pathologic features of glomerulosclerosis may be seen. In addition, pathologic sequelae of hypertension may be found elsewhere in the body. The presence of a PAN-like vasculitis in patients with hepatitis B together with the isolation of circulating immune complexes composed of hepatitis B antigen and immunoglobulin, and the demonstration by immunofluorescence of hepatitis B antigen, IgM, and complement in the blood vessel walls, strongly suggest the role of immunologic phenomena in the pathogenesis of this disease. Hairy cell leukemia can be associated with PAN; the pathogenic mechanisms of this association are unclear.

## Clinical and Laboratory Manifestations

Nonspecific signs and symptoms are the hallmarks of PAN. Fever, weight loss, and malaise are present in over one-half of cases. Patients usually present with vague symptoms such as weakness, malaise, headache, abdominal pain, and myalgias that can rapidly progress to a fulminant illness. In PAN, renal involvement most commonly manifests as hypertension, renal insufficiency, or hemorrhage due to microaneurysms.

There are no diagnostic serologic tests for PAN. In >75% of patients, the leukocyte count is elevated with a predominance of neutrophils. Eosinophilia is seen only rarely and, when present at high levels, suggests the diagnosis of Churg-Strauss syndrome. The anemia of chronic disease may be seen, and an elevated ESR is almost always present. Other common laboratory findings reflect the particular organ involved. Hypergammaglobulinemia may be present, and all patients should be screened for hepatitis B. Antibodies against myeloperoxidase or proteinase-3 (ANCA) are rarely found in patients with PAN.

## Diagnosis

The diagnosis of PAN is based on the demonstration of characteristic findings of vasculitis on biopsy material of involved organs. In the absence of easily accessible tissue for biopsy, the arteriographic demonstration of involved vessels, particularly in the form of aneurysms of small and medium-sized arteries in the renal, hepatic, and visceral vasculature, is sufficient to make the diagnosis. Aneurysms of vessels are not pathognomonic of PAN; furthermore, aneurysms need not always be present, and arteriographic findings may be limited to stenotic segments and

obliteration of vessels. Biopsy of symptomatic organs such as nodular skin lesions, painful testes, and nerve/muscle provides the highest diagnostic yields.

The prognosis of untreated PAN is extremely poor, with a reported 5-year survival rate between 10 and 20%. Death usually results from gastrointestinal complications, particularly bowel infarcts and perforation, and cardiovascular causes. Intractable hypertension often compounds dysfunction in other organ systems, such as the kidneys, heart, and CNS, leading to additional late morbidity and mortality in PAN. With the introduction of treatment, survival rate has increased substantially. Favorable therapeutic results have been reported in PAN with the combination of prednisone and cyclophosphamide (see "Granulomatosis With Polyangiitis (Wegener's)" for a detailed description of this therapeutic regimen). In less severe cases of PAN, glucocorticoids alone have resulted in disease remission. In patients with hepatitis B who have a PAN-like vasculitis, antiviral therapy represents an important part of therapy and has been used in combination with glucocorticoids and plasma exchange. Careful attention to the treatment of hypertension can lessen the acute and late morbidity and mortality rates associated with renal, cardiac, and CNS complications of PAN. Following successful treatment, relapse of PAN has been estimated to occur in 10–20% of patients. Following successful treatment, relapse of PAN has been estimated to occur in 10–20% of patients.

### **Giant Cell Arteritis and Polymyalgia Rheumatica**

#### **Definition**

*Giant cell arteritis*, also referred to as *cranial arteritis* or *temporal arteritis*, is an inflammation of medium- and large-sized arteries. It characteristically involves one or more branches of the carotid artery, particularly the temporal artery. However, it is a systemic disease that can involve arteries in multiple locations, particularly the aorta and its main branches.

Giant cell arteritis is closely associated with *polymyalgia rheumatica*, which is characterized by stiffness, aching, and pain in the muscles of the neck, shoulders, lower back, hips, and thighs. Most commonly, polymyalgia rheumatica occurs in isolation, but it may be seen in 40–50% of patients with giant cell arteritis. In addition, 10–20% of patients who initially present with features of isolated polymyalgia rheumatica later go on to develop giant cell arteritis. This strong clinical association together with data from pathophysiologic studies has increasingly supported that giant cell arteritis and polymyalgia rheumatica represent differing clinical spectrums of a single disease process.

#### **Pathology and Pathogenesis**

Although the temporal artery is most frequently involved in giant cell arteritis, patients often have a systemic vasculitis of multiple medium- and large-sized arteries, which may go undetected. Histopathologically, the disease is a panarteritis with inflammatory mononuclear cell infiltrates within the vessel wall with frequent giant cell formation. There is proliferation of the intima and fragmentation of the internal elastic lamina. Pathophysiologic findings in organs result from the ischemia related to the involved vessels.

Experimental data support that giant cell arteritis is an antigen-driven disease in which activated T lymphocytes, macrophages, and dendritic cells play a critical role in the disease pathogenesis. Sequence analysis of the T cell receptor of tissue-infiltrating T cells in lesions of giant cell arteritis indicates restricted clonal expansion, suggesting the presence of an antigen residing in the arterial wall. Giant cell arteritis is believed to be initiated in the adventitia where CD4+ T cells enter through the vasa vasorum, become activated, and orchestrate macrophage differentiation. T cells recruited to vasculitic lesions in patients with giant cell arteritis produce predominantly IL-2 and IFN- $\alpha$ , and the latter has been suggested to be involved in the progression to overt arteritis.

#### **Clinical and Laboratory Manifestations**

Giant cell arteritis is most commonly characterized clinically by the complex of fever, anemia, high ESR, and headaches in a patient over the age of 50 years. Other phenotypic manifestations include features of systemic inflammation including malaise, fatigue, anorexia, weight loss, sweats, arthralgias, polymyalgia rheumatica, or large-vessel disease.

In patients with involvement of the cranial arteries, headache is the predominant symptom and may be associated with a tender, thickened, or nodular artery, which may pulsate early in the disease but may become occluded later. Scalp pain and claudication of the jaw and tongue may occur. A well-recognized and dreaded complication of giant cell arteritis, particularly in untreated patients, is ischemic optic neuropathy, which may lead to serious visual symptoms, even sudden blindness in some patients. However, most patients have complaints relating to the head or eyes before visual loss. Attention to such symptoms with institution of appropriate therapy will usually avoid this complication. Other cranial ischemic complications include strokes, scalp or tongue infarction.

Up to one-third of patients can have large-vessel disease that can be the primary presentation of giant cell arteritis or can emerge at a later point in patients who have had previous cranial arteritis features or polymyalgia rheumatica. Manifestations of large-vessel disease can include subclavian artery stenosis that can present as arm claudication or aortic aneurysms involving the thoracic and to a lesser degree the abdominal aorta, which carry risks of rupture or dissection. Characteristic laboratory findings in addition to the elevated ESR include a normochromic or slightly hypochromic anemia. Liver function abnormalities are common, particularly increased alkaline phosphatase levels. Increased levels of IgG and complement have been reported. Levels of enzymes indicative of muscle damage such as serum creatine kinase are not elevated.

#### Diagnosis

The diagnosis of giant cell arteritis and its associated clinicopathologic syndrome can often be suggested clinically by the demonstration of the complex of fever, anemia, and high ESR with or without symptoms of polymyalgia rheumatica in a patient >50 years. The diagnosis is confirmed by biopsy of the temporal artery. Since involvement of the vessel may be segmental, positive yield is increased by obtaining a biopsy segment of 3–5 cm together with serial sectioning of biopsy specimens. Ultrasonography of the temporal artery has been reported to be helpful in diagnosis. A temporal artery biopsy should be obtained as quickly as possible in the setting of ocular signs and symptoms, and under these circumstances therapy should not be delayed pending a biopsy. In this regard, it has been reported that temporal artery biopsies may show vasculitis even after 14 days of glucocorticoid therapy. A dramatic clinical response to a trial of glucocorticoid therapy can further support the diagnosis.

Large vessel disease may be suggested by symptoms and findings on physical examination such as diminished pulses or bruits. It is confirmed by vascular imaging, most commonly through magnetic resonance or computed tomography.

Isolated polymyalgia rheumatica is a clinical diagnosis made by the presence of typical symptoms of stiffness, aching, and pain in the muscles of the hip and shoulder girdle, an increased ESR, the absence of clinical features suggestive of giant cell arteritis, and a prompt therapeutic response to low-dose prednisone.

#### Treatment: Giant Cell Arteritis and Polymyalgia Rheumatica

Acute disease-related mortality directly from giant cell arteritis is very uncommon with fatalities occurring from cerebrovascular events or myocardial infarction. However, patients are at risk of late mortality from aortic aneurysm rupture or dissection as patients with giant cell arteritis are 18 times more likely to develop thoracic aortic aneurysms than the general population.

The goals of treatment in giant cell arteritis are to reduce symptoms and, most importantly, to prevent visual loss. The treatment approach for cranial and large-vessel disease in giant cell arteritis is currently the same. Giant cell arteritis and its associated symptoms are exquisitely sensitive to glucocorticoid therapy. Treatment should begin with prednisone, 40–60 mg/d for 1 month, followed by a gradual tapering. When ocular signs and symptoms occur, consideration should be given for the use of methylprednisolone 1000 mg daily for 3 days to protect remaining vision. Although the optimal duration of glucocorticoid therapy has not been established, most series have found that patients require treatment for 2 years. Symptom recurrence during prednisone tapering develops in 60–85% of patients with giant cell arteritis, requiring a dosage increase. The ESR can serve as a useful indicator of inflammatory disease activity in monitoring

and tapering therapy and can be used to judge the pace of the tapering schedule. However, minor increases in the ESR can occur as glucocorticoids are being tapered and do not necessarily reflect an exacerbation of arteritis, particularly if the patient remains symptom-free. Under these circumstances, the tapering should continue with caution. Glucocorticoid toxicity occurs in 35–65% of patients and represents an important cause of patient morbidity. Aspirin 81 mg daily has been found to reduce the occurrence of cranial ischemic complications in giant cell arteritis and should be given in addition to glucocorticoids in patients who do not have contraindications. The use of weekly methotrexate as a glucocorticoid-sparing agent has been examined in two randomized placebo-controlled trials that reached conflicting conclusions. Infliximab, a monoclonal antibody to TNF, was studied in a randomized trial and was not found to provide benefit.

Patients with isolated polymyalgia rheumatica respond promptly to prednisone, which can be started at a lower dose of 10–20 mg/d. Similar to giant cell arteritis, the ESR can serve as a useful indicator in monitoring and prednisone reduction. Recurrent polymyalgia symptoms develop in the majority of patients during prednisone tapering. One study of weekly methotrexate found that the use of this drug reduced the prednisone dose on average by only 1 mg and did not decrease prednisone-related side effects. A randomized trial in polymyalgia rheumatica did not find infliximab to lessen relapse or glucocorticoid requirements.

**Takayasu's arteritis** is an inflammatory and stenotic disease of medium- and large-sized arteries characterized by a strong predilection for the aortic arch and its branches. For this reason, it is often referred to as the *aortic arch syndrome*.

#### Pathology and Pathogenesis

The disease involves medium- and large-sized arteries, with a strong predilection for the aortic arch and its branches; the pulmonary artery may also be involved. The involvement of the major branches of the aorta is much more marked at their origin than distally. The disease is a panarteritis with inflammatory mononuclear cell infiltrates and occasionally giant cells. There are marked intimal proliferation and fibrosis, scarring and vascularization of the media, and disruption and degeneration of the elastic lamina. Narrowing of the lumen occurs with or without thrombosis. The vasa vasorum are frequently involved. Pathologic changes in various organs reflect the compromise of blood flow through the involved vessels.

Immunopathogenic mechanisms, the precise nature of which is uncertain, are suspected in this disease. As with several of the vasculitis syndromes, circulating immune complexes have been demonstrated, but their pathogenic significance is unclear.

#### Clinical and Laboratory Manifestations

Takayasu's arteritis is a systemic disease with generalized as well as vascular symptoms. The generalized symptoms include malaise, fever, night sweats, arthralgias, anorexia, and weight loss, which may occur months before vessel involvement is apparent. These symptoms may merge into those related to vascular compromise and organ ischemia. Pulses are commonly absent in the involved vessels, particularly the subclavian artery. The frequency of arteriographic abnormalities and the potentially associated clinical manifestations are listed in Table 326-7.

Hypertension occurs in 32–93% of patients and contributes to renal, cardiac, and cerebral injury. Characteristic laboratory findings include an elevated ESR, mild anemia, and elevated immunoglobulin levels.

#### Diagnosis

The diagnosis of Takayasu's arteritis should be suspected strongly in a young woman who develops a decrease or absence of peripheral pulses, discrepancies in blood pressure, and arterial bruits. The diagnosis is confirmed by the characteristic pattern on arteriography, which includes irregular vessel walls, stenosis, poststenotic dilation, aneurysm formation, occlusion, and evidence of increased collateral circulation. Complete aortic arteriography by catheter-directed dye arteriography or magnetic resonance arteriography should be obtained in order to fully delineate the distribution and degree of arterial disease. Histopathologic demonstration of inflamed vessels adds confirmatory data; however, tissue is rarely readily available for

examination.

Treatment: Takayasu's Arteritis

The long-term outcome of patients with Takayasu's arteritis has varied widely between studies. Although two North American reports found overall survival to be >94%, the 5-year mortality rate from other studies has ranged from 0 to 35%. Disease-related mortality most often occurs from congestive heart failure, cerebrovascular events, myocardial infarction, aneurysm rupture, or renal failure. Even in the absence of life-threatening disease, Takayasu's arteritis can be associated with significant morbidity. The course of the disease is variable, and although spontaneous remissions may occur, Takayasu's arteritis is most often chronic and relapsing. Although glucocorticoid therapy in doses of 40–60 mg prednisone per day alleviates symptoms, there are no convincing studies that indicate that they increase survival. The combination of glucocorticoid therapy for acute signs and symptoms and an aggressive surgical and/or arterioplastic approach to stenosed vessels has markedly improved outcome and decreased morbidity by lessening the risk of stroke, correcting hypertension due to renal artery stenosis, and improving blood flow to ischemic viscera and limbs. Unless it is urgently required, surgical correction of stenosed arteries should be undertaken only when the vascular inflammatory process is well controlled with medical therapy. In individuals who are refractory to or unable to taper glucocorticoids, methotrexate in doses up to 25 mg per week has yielded encouraging results. Preliminary results with anti-TNF therapies have been encouraging, but will require further study through randomized trials to determine efficacy.

### **Henoch-Schönlein Purpura**

*Henoch-Schönlein purpura*, also referred to as *anaphylactoid purpura*, is a small-vessel vasculitis characterized by palpable purpura (most commonly distributed over the buttocks and lower extremities), arthralgias, gastrointestinal signs and symptoms, and glomerulonephritis.

#### **Pathology and Pathogenesis**

The presumptive pathogenic mechanism for Henoch-Schönlein purpura is immune-complex deposition. A number of inciting antigens have been suggested including upper respiratory tract infections, various drugs, foods, insect bites, and immunizations. IgA is the antibody class most often seen in the immune complexes and has been demonstrated in the renal biopsies of these patients.

#### **Clinical and Laboratory Manifestations**

In pediatric patients, palpable purpura is seen in virtually all patients; most patients develop polyarthralgias in the absence of frank arthritis. Gastrointestinal involvement, which is seen in almost 70% of pediatric patients, is characterized by colicky abdominal pain usually associated with nausea, vomiting, diarrhea, or constipation and is frequently accompanied by the passage of blood and mucus per rectum; bowel intussusception may occur. Renal involvement occurs in 10–50% of patients and is usually characterized by mild glomerulonephritis leading to proteinuria and microscopic hematuria, with red blood cell casts in the majority of patients; it usually resolves spontaneously without therapy. Rarely, a progressive glomerulonephritis will develop. In adults, presenting symptoms are most frequently related to the skin and joints, while initial complaints related to the gut are less common. Although certain studies have found that renal disease is more frequent and more severe in adults, this has not been a consistent finding. However, the course of renal disease in adults may be more insidious and thus requires close follow-up. Myocardial involvement can occur in adults but is rare in children.

Laboratory studies generally show a mild leukocytosis, a normal platelet count, and occasionally eosinophilia. Serum complement components are normal, and IgA levels are elevated in about one-half of patients.

#### **Diagnosis**

The diagnosis of Henoch-Schönlein purpura is based on clinical signs and symptoms. Skin biopsy specimen can be useful in confirming leukocytoclastic vasculitis with IgA and C3 deposition by immunofluorescence. Renal biopsy is rarely needed for diagnosis but may provide prognostic information in some patients.

### Treatment: Henoch-Schönlein Purpura

The prognosis of Henoch-Schönlein purpura is excellent. Mortality is exceedingly rare, and 1–5% of children progress to end-stage renal disease. Most patients recover completely, and some do not require therapy. Treatment is similar for adults and children. When glucocorticoid therapy is required, prednisone, in doses of 1 mg/kg per day and tapered according to clinical response, has been shown to be useful in decreasing tissue edema, arthralgias, and abdominal discomfort; however, it has not proved beneficial in the treatment of skin or renal disease and does not appear to shorten the duration of active disease or lessen the chance of recurrence. Patients with rapidly progressive glomerulonephritis have been anecdotally reported to benefit from intensive plasma exchange combined with cytotoxic drugs. Disease recurrences have been reported in 10–40% of patients.

### Idiopathic Cutaneous Vasculitis

The term *cutaneous vasculitis* is defined broadly as inflammation of the blood vessels of the dermis. Due to its heterogeneity, cutaneous vasculitis has been described by a variety of terms including *hypersensitivity vasculitis* and *cutaneous leukocytoclastic angiitis*. However, cutaneous vasculitis is not one specific disease but a manifestation that can be seen in a variety of settings. In >70% of cases, cutaneous vasculitis occurs either as part of a primary systemic vasculitis or as a secondary vasculitis related to an inciting agent or an underlying disease (see "Secondary Vasculitis," below). In the remaining 30% of cases, cutaneous vasculitis occurs idiopathically.

#### Pathology and Pathogenesis

The typical histopathologic feature of cutaneous vasculitis is the presence of vasculitis of small vessels. Postcapillary venules are the most commonly involved vessels; capillaries and arterioles may be involved less frequently. This vasculitis is characterized by a *leukocytoclasia*, a term that refers to the nuclear debris remaining from the neutrophils that have infiltrated in and around the vessels during the acute stages. In the subacute or chronic stages, mononuclear cells predominate; in certain subgroups, eosinophilic infiltration is seen. Erythrocytes often extravasate from the involved vessels, leading to palpable purpura.

#### Clinical and Laboratory Manifestations

The hallmark of idiopathic cutaneous vasculitis is the predominance of skin involvement. Skin lesions may appear typically as palpable purpura; however, other cutaneous manifestations of the vasculitis may occur, including macules, papules, vesicles, bullae, subcutaneous nodules, ulcers, and recurrent or chronic urticaria. The skin lesions may be pruritic or even quite painful, with a burning or stinging sensation. Lesions most commonly occur in the lower extremities in ambulatory patients or in the sacral area in bedridden patients due to the effects of hydrostatic forces on the postcapillary venules. Edema may accompany certain lesions, and hyperpigmentation often occurs in areas of recurrent or chronic lesions.

There are no specific laboratory tests diagnostic of idiopathic cutaneous vasculitis. A mild leukocytosis with or without eosinophilia is characteristic, as is an elevated ESR. Laboratory studies should be aimed toward ruling out features to suggest an underlying disease or a systemic vasculitis.

#### Diagnosis

The diagnosis of cutaneous vasculitis is made by the demonstration of vasculitis on biopsy. An important diagnostic principle in patients with cutaneous vasculitis is to search for an etiology of the vasculitis—be it an exogenous agent, such as a drug or an infection, or an endogenous condition, such as an underlying disease (Fig. 326-1). In addition, a careful physical and laboratory examination should be performed to rule out the possibility of systemic vasculitis. This should start with the least invasive diagnostic approach and proceed to the more invasive only if clinically indicated.

#### Treatment: Idiopathic Cutaneous Vasculitis

When an antigenic stimulus is recognized as the precipitating factor in the cutaneous vasculitis, it should be removed; if this is a microbe, appropriate antimicrobial therapy should be instituted. If the vasculitis is associated with another underlying disease, treatment of the latter often results in

resolution of the former. In situations where disease is apparently self-limited, no therapy, except possibly symptomatic therapy, is indicated. When cutaneous vasculitis persists and when there is no evidence of an inciting agent, an associated disease, or an underlying systemic vasculitis, the decision to treat should be based on weighing the balance between the degree of symptoms and the risk of treatment. Some cases of idiopathic cutaneous vasculitis resolve spontaneously, while others remit and relapse. In those patients with persistent vasculitis, a variety of therapeutic regimens have been tried with variable results. In general, the treatment of idiopathic cutaneous vasculitis has not been satisfactory. Fortunately, since the disease is generally limited to the skin, this lack of consistent response to therapy usually does not lead to a life-threatening situation. Agents with which there have been anecdotal reports of success include dapsone, colchicine, hydroxychloroquine, and nonsteroidal anti-inflammatory agents. Glucocorticoids are often used in the treatment of idiopathic cutaneous vasculitis. Therapy is usually instituted as prednisone, 1 mg/kg per day, with rapid tapering where possible, either directly to discontinuation or by conversion to an alternate-day regimen followed by ultimate discontinuation. In cases that prove refractory to glucocorticoids, a trial of a cytotoxic agent may be indicated. Patients with chronic vasculitis isolated to cutaneous venules rarely respond dramatically to any therapeutic regimen, and cytotoxic agents should be used only as a last resort in these patients. Methotrexate and azathioprine have been used in such situations in anecdotal reports. Although cyclophosphamide is the most effective therapy for the systemic vasculitides, it should almost never be used for idiopathic cutaneous vasculitis because of the potential toxicity.

### **Cryoglobulinemic Vasculitis**

Cryoglobulins are cold-precipitable monoclonal or polyclonal immunoglobulins.

Cryoglobulinemia may be associated with a systemic vasculitis characterized by palpable purpura, arthralgias, weakness, neuropathy, and glomerulonephritis. Although this can be observed in association with a variety of underlying disorders including multiple myeloma, lymphoproliferative disorders, connective tissue diseases, infection, and liver disease, in many instances it appeared to be idiopathic. Because of the apparent absence of an underlying disease and the presence of cryoprecipitate containing oligoclonal/polyclonal immunoglobulins, this entity was referred to as *essential mixed cryoglobulinemia*. Since the discovery of hepatitis C, it has been established that the vast majority of patients who were considered to have essential mixed cryoglobulinemia have cryoglobulinemic vasculitis related to hepatitis C infection.

#### **Pathology and Pathogenesis**

Skin biopsies in cryoglobulinemic vasculitis reveal an inflammatory infiltrate surrounding and involving blood vessel walls, with fibrinoid necrosis, endothelial cell hyperplasia, and hemorrhage. Deposition of immunoglobulin and complement is common. Abnormalities of uninvolved skin including basement membrane alterations and deposits in vessel walls may be found. Membranoproliferative glomerulonephritis is responsible for 80% of all renal lesions in cryoglobulinemic vasculitis.

The association between hepatitis C and cryoglobulinemic vasculitis has been supported by the high frequency of documented hepatitis C infection, the presence of hepatitis C RNA and anti-hepatitis C antibodies in serum cryoprecipitates, evidence of hepatitis C antigens in vasculitic skin lesions, and the effectiveness of antiviral therapy. Current evidence suggests that in the majority of cases, cryoglobulinemic vasculitis occurs when an aberrant immune response to hepatitis C infection leads to the formation of immune complexes consisting of hepatitis C antigens, polyclonal hepatitis C-specific IgG, and monoclonal IgM rheumatoid factor. The deposition of these immune complexes in blood vessel walls triggers an inflammatory cascade that results in cryoglobulinemic vasculitis.

#### **Clinical and Laboratory Manifestations**

The most common clinical manifestations of cryoglobulinemic vasculitis are cutaneous vasculitis, arthritis, peripheral neuropathy, and glomerulonephritis. Renal disease develops in 10–30% of patients. Life-threatening rapidly progressive glomerulonephritis or vasculitis of the CNS, gastrointestinal tract, or heart occurs infrequently.

The presence of circulating cryoprecipitates is the fundamental finding in cryoglobulinemic vasculitis. Rheumatoid factor is almost always found and may be a useful clue to the disease when cryoglobulins are not detected. Hypocomplementemia occurs in 90% of patients. An elevated ESR and anemia occur frequently. Evidence for hepatitis C infection must be sought in all patients by testing for hepatitis C antibodies and hepatitis C RNA.

#### **Treatment: Cryoglobulinemic Vasculitis**

Acute mortality directly from cryoglobulinemic vasculitis is uncommon, but the presence of glomerulonephritis is a poor prognostic sign for overall outcome. In such patients, 15% progress to end-stage renal disease, with 40% later experiencing fatal cardiovascular disease, infection, or liver failure. As indicated above, the majority of cases are associated with hepatitis C infection. In such patients, treatment with IFN- $\alpha$  and ribavirin can prove beneficial. Clinical improvement with antiviral therapy is dependent on the virologic response. Patients who clear hepatitis C from the blood have objective improvement in their vasculitis along with significant reductions in levels of circulating cryoglobulins, IgM, and rheumatoid factor. However, substantial portions of patients with hepatitis C do not have a sustained virologic response to such therapy, and the vasculitis typically relapses with the return of viremia. While transient improvement can be observed with glucocorticoids, a complete response is seen in only 7% of patients.

Plasmapheresis and cytotoxic agents have been used in anecdotal reports. These observations have not been confirmed, and such therapies carry significant risks.

#### **Behçet's Syndrome**

*Behçet's syndrome* is a clinicopathologic entity characterized by recurrent episodes of oral and genital ulcers, iritis, and cutaneous lesions. The underlying pathologic process is a leukocytoclastic venulitis, although vessels of any size and in any organ can be involved.

#### **Isolated Vasculitis of the Central Nervous System**

*Isolated vasculitis of the CNS*, which is also called *primary angiitis of the CNS* (PACNS), is an uncommon clinicopathologic entity characterized by vasculitis restricted to the vessels of the CNS without other apparent systemic vasculitis. The inflammatory process is usually composed of mononuclear cell infiltrates with or without granuloma formation.

Patients may present with headaches, altered mental function, and focal neurologic defects. Systemic symptoms are generally absent. Devastating neurologic abnormalities may occur depending on the extent of vessel involvement. The diagnosis can be suggested by abnormal MRI of the brain, an abnormal lumbar puncture, and/or demonstration of characteristic vessel abnormalities on arteriography, but it is confirmed by biopsy of the brain parenchyma and leptomeninges. In the absence of a brain biopsy, care should be taken not to misinterpret as true primary vasculitis arteriographic abnormalities that might actually be related to another cause. An important entity in the differential diagnosis is reversible cerebral vasoconstrictive syndrome, which typically presents with "thunderclap" headache and is associated with arteriographic abnormalities that mimic PACNS that are reversible. Other diagnostic considerations include infection, atherosclerosis, emboli, connective tissue disease, sarcoidosis, malignancy, and drug-associated causes. The prognosis of granulomatous PACNS is poor; however, some reports indicate that glucocorticoid therapy, alone or together with cyclophosphamide administered as described above, has induced clinical remissions.

#### **Cogan's Syndrome**

*Cogan's syndrome* is characterized by interstitial keratitis together with vestibuloauditory symptoms. It may be associated with a systemic vasculitis, particularly aortitis with involvement of the aortic valve. Glucocorticoids are the mainstay of treatment. Initiation of treatment as early as possible after the onset of hearing loss improves the likelihood of a favorable outcome.

#### **Kawasaki Disease**

*Kawasaki disease*, also referred to as *mucocutaneous lymph node syndrome*, is an acute, febrile, multisystem disease of children. Some 80% of cases occur prior to the age of 5, with the peak incidence occurring at 2 years. It is characterized by nonsuppurative cervical adenitis and changes in the skin and mucous membranes such as edema; congested conjunctivae; erythema of



the oral cavity, lips, and palms; and desquamation of the skin of the fingertips. Although the disease is generally benign and self-limited, it is associated with coronary artery aneurysms in 25% of cases, with an overall case-fatality rate of 0.5–2.8%. These complications usually occur between the third and fourth weeks of illness during the convalescent stage. Vasculitis of the coronary arteries is seen in almost all the fatal cases that have been autopsied. There is typical intimal proliferation and infiltration of the vessel wall with mononuclear cells. Beadlike aneurysms and thromboses may be seen along the artery. Other manifestations include pericarditis, myocarditis, myocardial ischemia and infarction, and cardiomegaly.

Apart from the up to 2.8% of patients who develop fatal complications, the prognosis of this disease for uneventful recovery is excellent. High-dose IV  $\gamma$ -globulin (2 g/kg as a single infusion over 10 h) together with aspirin (100 mg/kg per day for 14 days followed by 3–5 mg/kg per day for several weeks) have been shown to be effective in reducing the prevalence of coronary artery abnormalities when administered early in the course of the disease. Surgery may be necessary for Kawasaki disease patients that have giant coronary artery aneurysms or other coronary complications. Surgical treatment most commonly includes thromboendarterectomy, thrombus clearing, aneurysmal reconstruction, and coronary artery bypass grafting.

### **Polyangiitis Overlap Syndromes**

Some patients with systemic vasculitis manifest clinicopathologic characteristics that do not fit precisely into any specific disease but have overlapping features of different vasculitides. Active systemic vasculitis in such settings has the same potential for causing irreversible organ system damage as when it occurs in one of the defined syndromes listed in Table 326-1. The diagnostic and therapeutic considerations as well as the prognosis for these patients depend on the sites and severity of active vasculitis. Patients with vasculitis that could potentially cause irreversible damage to a major organ system should be treated as described under "Granulomatosis With Polyangiitis (Wegener's)."

### **Secondary Vasculitis**

#### **Drug-Induced Vasculitis**

Vasculitis associated with drug reactions usually presents as palpable purpura that may be generalized or limited to the lower extremities or other dependent areas; however, urticarial lesions, ulcers, and hemorrhagic blisters may also occur. Signs and symptoms may be limited to the skin, although systemic manifestations such as fever, malaise, and polyarthralgias may occur. Although the skin is the predominant organ involved, systemic vasculitis may result from drug reactions. Drugs that have been implicated in vasculitis include allopurinol, thiazides, gold, sulfonamides, phenytoin, and penicillin.

An increasing number of drugs have been reported to cause vasculitis associated with antineutrophil cytoplasmic ANCA. Of these, the best evidence of causality exists for hydralazine and propylthiouracil. The clinical manifestations in ANCA-positive drug-induced vasculitis can range from cutaneous lesions to glomerulonephritis and pulmonary hemorrhage. Outside of drug discontinuation, treatment should be based on the severity of the vasculitis. Patients with immediately life-threatening small-vessel vasculitis should initially be treated with glucocorticoids and cyclophosphamide as described for granulomatosis with polyangiitis (Wegener's). Following clinical improvement, consideration may be given for tapering such agents along a more rapid schedule.

### **Serum Sickness and Serum Sickness–Like Reactions**

These reactions are characterized by the occurrence of fever, urticaria, polyarthralgias, and lymphadenopathy 7–10 days after primary exposure and 2–4 days after secondary exposure to a heterologous protein (classic serum sickness) or a nonprotein drug such as penicillin or sulfa (serum sickness–like reaction). Most of the manifestations are not due to a vasculitis; however, occasional patients will have typical cutaneous venulitis that may progress rarely to a systemic vasculitis.

### **Vasculitis Associated with Other Underlying Diseases**

Certain *infections* may directly trigger an inflammatory vasculitic process. For example,

rickettsias can invade and proliferate in the endothelial cells of small blood vessels causing a vasculitis. In addition, the inflammatory response around blood vessels associated with certain systemic fungal diseases such as histoplasmosis may mimic a primary vasculitic process. A leukocytoclastic vasculitis predominantly involving the skin with occasional involvement of other organ systems may be a minor component of many other infections. These include *subacute bacterial endocarditis*, *Epstein-Barr virus infection*, *HIV infection*, as well as a number of other infections.

Vasculitis can be associated with certain *malignancies*, particularly lymphoid or reticuloendothelial neoplasms. Leukocytoclastic venulitis confined to the skin is the most common finding; however, widespread systemic vasculitis may occur. Of particular note is the association of *hairy cell leukemia* with PAN.

A number of *connective tissue diseases* have vasculitis as a secondary manifestation of the underlying primary process. Foremost among these are *systemic lupus erythematosus*, *rheumatoid arthritis*, *inflammatory myositis*, *relapsing polychondritis*, and *Sjögren's syndrome*. The most common form of vasculitis in these conditions is the small-vessel venulitis isolated to the skin. However, certain patients may develop a fulminant systemic necrotizing vasculitis. Secondary vasculitis has also been observed in association with *ulcerative colitis*, *congenital deficiencies of various complement components*, *retroperitoneal fibrosis*, *primary biliary cirrhosis*,  $\alpha_1$ -antitrypsin deficiency, and *intestinal bypass surgery*.

#### Tests for self-control:

1. A 30 y.o. female with rheumatoid arthritis of five years duration complains of pain in the first three fingers of her right hand over past 6 weeks. The pain seems especially severe at night often awakening her from sleep. The most likely cause is?

- A** Carpal tunnel syndrome
- B** Atlanto-axial subluxation of cervical spine
- C** Sensory peripheral neuropathy
- D** Rheumatoid vasculitis
- E** Rheumatoid arthritis without complication

2. A 16 y.o. female presents with abdominal pain and purpuric spots on the skin. Laboratory investigations reveals a normal platelet count, with haematuria and proteinuria. The most likely diagnosis:

- A** Schonlein-Henoch purpura
- B** Haemolytic uraemic syndrome
- C** Thrombotic thrombocytopenic purpura
- D** Heavy metal poisoning

#### Answers

- 1. c
- 2. a

## **1. The aims of the training course:**

### **To Know:**

8. Differential diagnosis of thrombocytopenic purpura.
9. Mechanisms of hemolysis.
10. Clinical and laboratory diagnosis of different forms.
11. Complications.
12. Treatment.
13. Transfusion of blood components.
14. Primary and secondary prevention.
15. Weather and performance..

### **To be able to:**

- Conduct surveys and examination the patients with major haematological syndromes
- justify the use of basic diagnostic methods used in hematology, indications and contraindications for their conduction, possible complications
- Identify typical and atypical clinical picture of major diseases and blood forming organs
- draft examination of patients
- Based on analysis of laboratory and instrumental examination to conduct differential diagnosis, justify and formulate diagnoses for major diseases and blood forming organs
- prescribe treatment, determine prognosis, to conduct primary and secondary prevention in major diseases and blood forming organs
- diagnose and assist with hemorrhage due to diseases of blood and blood forming organs
- Identify blood transfuse blood components and blood substitutes

### **The contents of topic:**

#### **Text**

Chronic ITP is an autoimmune disorder in which normal proteins located on the platelet surface act as antigens and stimulate the immune system to produce autoantibody and specific cytotoxic T lymphocytes. Why these platelet proteins are recognized as 'foreign' by the immune system is not known.

#### **Platelet production in the bone marrow and survival in the bloodstream.**

Platelets are produced in the bone marrow by large cells called megakaryocytes. These cells are stimulated to multiply and produce platelets primarily by a substance called thrombopoietin. Once platelets are released from the bone marrow, they normally circulate in the blood for 8-10 days. In patients with chronic ITP, platelet survival in the blood is reduced due to their destruction (sometimes as short as a few hours) and the patient develops a low platelet count (thrombocytopenia). Platelet destruction occurs mainly in the spleen and to some extent in the liver and bone marrow.

#### **Antiplatelet autoantibody.**

Studies in the 1950's showed that transfusion of blood or plasma from a patient with chronic ITP into a normal volunteer subject caused thrombocytopenia. Subsequent studies showed that the substance in the blood of ITP patients that destroys platelets is an autoantibody. In most patients, the autoantibody binds to an antigen on one of the protein complexes (a complex is a combination of two or more proteins) on the platelet surface. The majority of patients have antibodies which bind to either the platelet glycoprotein IIb/IIIa complex (a combination of glycoprotein IIb and glycoprotein IIIa) or the platelet glycoprotein Ib/IX complex (a combination of glycoprotein Ib and glycoprotein IX); in the other patients, the location of the antigen on the platelet is not known. Since these glycoprotein complexes are also present on the megakaryocyte, the autoantibody in chronic ITP may also affect platelet production. The spleen is the most important site of antibody production in chronic ITP, although autoantibody is also produced in the bone marrow.

#### **Cytotoxic thymic-dependent (T) lymphocytes.**

These specialized white blood cells are produced in the bone marrow and then mature in the thymus gland. They have receptors on their surface that are programmed to bind to a specific antigen that, in the case of ITP, is on the surface of platelets and probably megakaryocytes.

Cytotoxic T lymphocytes may circulate in the blood but are primarily localized in the spleen and lymph nodes.

### **Causes of thrombocytopenia in ITP.**

**Platelet destruction.** Platelet destruction in chronic ITP is due to either: (1) antibody binding to a platelet autoantigen(s) followed by phagocytosis of the platelets by white blood cells (neutrophils or monocytes) or (2) binding of cytotoxic T lymphocytes to platelets followed by release of toxins causing platelet death. For platelet destruction by antibody to occur, three things must be present: sufficient antigen (platelets), autoantibody and phagocytic cells. The spleen is an optimal location for this. About one third of the circulating platelets are in the spleen at all times and the production of antiplatelet antibody in the spleen subjects these platelets to high antibody concentrations. The antibody-sensitized platelets circulate slowly through the spleen, which is rich in the phagocytic cells that destroy them. Concurrently, cytotoxic T lymphocytes are reacting with antigens on platelets, adding to the destruction of platelets. Removal of the spleen results in the cure of many ITP patients. In patients who have no spleen, the antibody is produced mostly in the bone marrow, and the antibody-sensitized platelets are destroyed in either the bone marrow or liver.

**Suppression of platelet production.** The bone marrow is capable of increasing the production of platelets up to 6 to 8 times normal, if necessary. However, platelet production in most ITP patients is less than would be expected, in view of the ongoing platelet destruction. This suggests that, in some patients, the autoantibody and probably the cytotoxic T lymphocytes may also damage megakaryocytes and inhibit platelet production. There is experimental evidence to show that autoantibody can suppress platelet production; studies have not been done, thus far, to evaluate the role of cytotoxic T lymphocytes.

**Clinical findings.** Patients may have no symptoms and the low platelet count may be noted during routine blood studies. However, most patients see their doctor because they develop a skin rash on their legs (called petechiae, a collection of small pinpoint bruises), excessive bruising or, less commonly, bleeding from the nose, gums or rarely from the gastrointestinal tract (stomach or bowel) or genitourinary tract (blood in the urine). Women may note prolonged or heavy menstrual bleeding. Symptoms may be exaggerated by certain medications which interfere with platelet function (e.g., aspirin, ibuprofen).

**Laboratory findings.** The blood count is normal except for a low platelet count (a normal platelet count in our laboratory is 130,000 to 400,000). Occasionally, patients are anemic if significant bleeding has occurred. Bone marrow examination is normal except that the number megakaryocytes (the cells which produce platelets) is often increased since the body is attempting to respond to the destruction of platelets by increasing their production. Autoantibodies against platelets can be detected in most patients. In chronic ITP, all other laboratory tests should be normal (including tests to rule out HIV, hepatitis or cytomegalovirus infection).

**Indications for treatment.** Treatment is indicated only in patients who are unable to maintain platelet counts consistently over 25-30,000. There are occasional exceptions to this (patients should discuss this with their doctor). Patients whose lifestyle involves a significant risk of injury (e.g., a professional football player) will require higher platelet counts for safety.

**General treatment recommendations.** Patients with low platelet counts should: (1) avoid aspirin or non-steroidal anti-inflammatory drugs, such as ibuprofen, since these agents may interfere with platelet function and induce bleeding. For mild pain relief, acetaminophen (Tylenol) is safe since it does not affect platelet function; (2) avoid situations where significant injury could occur (e.g., football, skiing, sky diving, etc.)

### ***Emergency Treatment of Chronic ITP.***

Occasionally, patients with chronic ITP will have severe and potentially life-threatening bleeding. Patients with severe bleeding, due to very low platelet counts (usually less than 5,000), are given one of the following treatments. The results with each treatment are similar. Most patients respond within several hours by increasing their platelet count to safe levels.

1. *Intravenous gammaglobulin.* Usually 50 to 100 grams is given intravenously daily for 1-3 days.
2. *High-dose corticosteroids.* Usually 1 gram of methylprednisolone is given intravenously daily for 3 days. An equivalent dose of another corticosteroid may also be used.
3. *Both therapies.* Rarely, in extreme circumstances, both intravenous gammaglobulin and high-dose corticosteroids are given.

In addition to one of the above treatments, platelet transfusions are given as often as necessary until bleeding has stopped.

**Note.** One study reported that anti-D therapy, given at a higher dose than usual (75 ug/kg/d), may also be useful under emergency circumstances.

### **Recommended Initial Treatment of Adult ITP**

#### **Summary of Initial Treatment.**

1. Corticosteroids: prednisone. Begin prednisone as the first treatment, in view of its convenience (pills) and low cost. Start with high doses (50-100 mg/d) and taper the dose as the platelet count increases, with the aim of maintaining safe platelet counts on doses which do not cause significant side effects (~10-15 mg/day).
2. Corticosteroids: high-dose dexamethasone. An alternate treatment method for giving corticosteroids has been reported with encouraging results in a substantial number of patients (Blood 109:1401, 2007). This treatment uses very high doses of dexamethasone given in one of two ways: (1) dexamethasone, 40 mg per day for 4 consecutive days, given every 28 days for 6 courses or (2) dexamethasone, 40 mg per day for 4 consecutive days, given every 14 days for 4 courses. Persistent complete responses were noted in about two thirds of the adult patients with an average followup of about 2 years. For further details, discuss this protocol with your doctor.
3. Anti-D. In Rh positive patients, who either do not respond to prednisone or dexamethasone or whose prednisone dose can not be tapered within a few weeks to doses which are not associated with side effects, anti-D should be substituted. Anti-D is administered whenever the platelet count falls below 25-30,000. Note: anti-D is not useful in Rh negative patients.

This approach should be continued for at least 6-12 months if possible. The exact duration of this therapy must be decided by the patient and treating physician since there are no studies available to determine how long this approach should be pursued before advising removal of the spleen (splenectomy).

4. Splenectomy. Splenectomy is recommended if: (a) the platelet count can not be maintained at safe levels using these measures; (b) the physician feels that a spontaneous remission is unlikely to occur or (c) if the approach becomes too burdensome for the patient (frequent blood tests, office visits, lost work time, etc).

#### **Treatment Details.**

**Prednisone (corticosteroids).** About three-fourths of patients will increase their platelet count on treatment and about one-half will attain normal platelet counts. In some patients, the platelet count can be maintained at safe levels, after tapering to prednisone doses which are not associated with side effects. However, many patients will note an initial improvement in their platelet count with high doses of steroids but, when the dose is lowered, will relapse.

**Dose.** The starting oral dose of prednisone is 50-100 mg/day depending on the patient's weight. This dose is usually continued for no more than 4-6 weeks. If a normal platelet count is attained, the dose is gradually tapered over several weeks to the lowest dose which will maintain safe platelet counts.

**Side effects.** These occur only at high doses over a period of time. They include gradual swelling of the face, neck and shoulders; fluid retention; gastric hyperacidity (heartburn); anxiety, difficulty sleeping and potassium loss. Osteoporosis (thinning of the bones) and an increased risk of infection may be problems if treatment is given over several months. Since hyperacidity is common, antacids or acid inhibitors are often needed. The serum potassium should be monitored and potassium supplements given as required.

**High-dose dexamethasone (corticosteroids).** This form of corticosteroid therapy may be recommended instead of prednisone. Side effects are similar but, due to the high doses, may be more pronounced. Details concerning dosage and side effects should be discussed with your doctor.

**Anti-D (Winrho SDF).** About two-thirds of Rh positive ITP patients will respond consistently to this drug. Rh negative patients should not receive this treatment since it will be ineffective.  
**Dose.** The standard dose is 50 ug/kg/d by intravenous injection over 3-5 minutes. Although recent data show a better and more prolonged response to 75 ug/kg/d, this higher dose is associated with more side effects. Injections are advised anytime the platelet count falls below 30,000.

**Side effects.** Most side effects occur during or shortly after anti-D injection and include: fever, chills and headache. Rarely, severe anemia may occur (requiring red cell transfusion) and, in a small number of cases, this has been associated with kidney failure and death.

**Splenectomy (removal of the spleen).** Splenectomy gives the highest cure rate of all treatments. In a recent review of the results of several large studies (47 studies) with long followup, splenectomy resulted in a permanent complete response (normal platelet count on no treatment) in 1761 of 2623 patients (66%). If only patients with followup of more than 5 years were evaluated, the same results were noted: 456 of 707 (65%) were in complete remission with an average followup of 7.3 years. Therefore, two thirds of ITP patients require no additional treatment for their ITP after splenectomy.

**Who will respond?** At present, there is no way to predict, prior to surgery, who will respond to splenectomy. One article suggested that patients whose platelet count increases after treatment with intravenous gammaglobulin are more likely to respond to splenectomy (Law C, Marcaccio M, Tam P et al. New England Journal of Medicine 336:1494, 1997). However, other groups could not confirm this result.

**Surgical Method.** There are two ways to remove the spleen: (1) abdominal surgery through a standard incision (the old-fashioned way) or (2) laparoscopy, where several small incisions are made in the abdomen and a telescope-like instrument (laparoscope) is inserted. After the blood vessels are tied, the spleen is encased in a bag and ground up so that it can be removed through the small opening. Laparoscopic surgery is associated with less post-operative side effects, a shorter recovery period and results are as good as those obtained with 'standard' surgery. If this method is chosen, be sure that the surgeon has experience with this approach (has performed ~20 such procedures) since there is a 'learning curve'.

**Post-operative Course.** The platelet count increases rapidly after surgery with normal counts appearing within 2 weeks in most responding patients. About one third of patients either fail to respond to splenectomy or develop recurrent thrombocytopenia after an initial response, usually within a few weeks after surgery. Youth, a short disease duration and an increase in the platelet count to greater than 400-600,000 after surgery are good prognostic signs.

**Side effects.** Surgical mortality is extremely low and is primarily due to the risk of anesthesia. Although the risk of overwhelming infection after splenectomy is substantial in young children (less than 6 years old), this is rare in adults and should not influence the decision to have surgery. Prior to surgery, each patient should be vaccinated against the common bacteria (germs) that can cause serious infection in patients who have no spleen: pneumococcus, Hemophilus influenza and meningococcus. Wound infection, post-operative bleeding, pneumonia, etc. may occur but these problems are uncommon.

**Accessory spleens.** Some ITP patients who relapse at a later time after surgery have an accessory spleen (small amounts of splenic tissue that are not connected to the main organ which may not have been removed at the time of surgery). All patients who relapse after surgery should be evaluated for an accessory spleen. If present, strong consideration should be given for their removal unless there is some medical reason that prevents surgery.

### ***Treatment of Refractory ITP Patients***

#### **First line therapy.**

- Corticosteroids
- Danazol (Danocrine)
- Colchicine
- Dapsone

#### **Second line therapy.**

- Cyclophosphamide (Cytosan)
- Azathioprine (Imuran)
- Mycophenolate mofetil (Cellcept)
- Cyclosporine

**Third line therapy- aggressive chemotherapy.**

- High-dose cyclophosphamide
- Combination chemotherapy

**Fourth Line Therapy- treatments with various limitations.**

- Ascorbic acid (vitamin C)
- Gammaglobulin (long-term)
- Vinblastine (long-term)

**Self-training at classes:**

Listen information;

Work with patients (with cardiac pathology);

Ask about the problems that have not been found in information given.

**Self -training at home:**

Compose the plan of your answer;

Answer the questions to the topic;

Do the test given above.

1. A 22-year-old African American male wants to know if he has sickle cell trait. He has no previous history of the signs or symptoms of sickle cell anemia. What laboratory method or test can be used to detect the presence of hemoglobin S?

- Coombs' test
- Metabisulfite test
- Osmotic fragility test
- Schilling test
- Sucrose hemolysis test

2. Deletion of all four normal  $\alpha$ -globin genes will most likely produce a.  $\alpha$  thalassemia minor

- $\beta$  thalassemia minor
- Cooley's anemia
- Hemoglobin H disease
- Hydrops fetalis

3. Hemoglobin electrophoresis of the blood from an individual with Cooley's anemia ( $\beta$  thalassemia major) would most likely show which one of the following combinations of findings?

**Hemoglobin A    Hemoglobin A2    Hemoglobin F**

- Increased      Increased      Increased
- Increased      Increased      Decreased
- Increased      Decreased      Increased
- Decreased      Increased      Increased
- Decreased      Decreased      Decreased

**References**

1. Chiao EY, Engels EA, Kramer JR, et al. Risk of immune thrombocytopenic purpura and autoimmune hemolytic anemia among 120 908 US veterans with hepatitis C virus infection. *Arch Intern Med.* Feb 23 2009;169(4):357-63. [\[Medline\]](#).
2. Hashimoto C. Autoimmune hemolytic anemia. *Clin Rev Allergy Immunol.* Fall 1998;16(3):285-95. [\[Medline\]](#).
3. Packman CH. Hemolytic anemia due to warm autoantibodies. *Blood Rev.* Jan 2008;22(1):17-31. [\[Medline\]](#).
4. Mayer B, Yurek S, Kiesewetter H, Salama A. Mixed-type autoimmune hemolytic anemia: differential diagnosis and a critical review of reported cases. *Transfusion.* Oct 2008;48(10):2229-34. [\[Medline\]](#).
5. Sanz J, Arriaga F, Montesinos P, et al. Autoimmune hemolytic anemia following



allogeneic hematopoietic stem cell transplantation in adult patients. *Bone Marrow Transplant.* May 2007;39(9):555-61. [\[Medline\]](#).

1. The answer is b. The metabisulfite test is used to detect the presence of hemoglobin S, but it does not differentiate the heterozygous sickle cell trait from the homozygous sickle cell disease. The test is based on the fact that erythrocytes with a large proportion of hemoglobin S sickle in solutions of low oxygen content. Metabisulfite is a reducing substance that enhances the process of deoxygenation. The osmotic fragility test is a diagnostic test for hereditary spherocytosis. Spherocytes lyse at a higher concentration of salt than do normal cells, thus causing an increased osmotic fragility. The direct antiglobulin test (DAT), or Coombs' test, is used to differentiate autoimmune hemolytic anemia (AIHA) due to the presence of anti-red cell antibodies from other forms of hemolytic anemia. In this test, antibodies to human immunoglobulin cause the agglutination (clotting) of red cells if these anti-red cell antibodies are present on the surface of the red cells. In patients with paroxysmal nocturnal hemoglobinuria, the erythrocytes are excessively sensitive to complement-mediated lysis in low ionic environments (the basis for the sucrose hemolysis test) or in acidotic conditions, such as sleep, exercise, or the Ham's acid hemolysis test. The Schilling test, which measures intestinal absorption of vitamin B12 with and without intrinsic factor, is used to diagnose decreased vitamin B12 caused by pernicious anemia, which is characterized by a lack of intrinsic factor.

2. The answer is e. The thalassemia syndromes are characterized by a decreased or absent synthesis of either the  $\alpha$ - or the  $\beta$ -globin chain of hemoglobin A ( $\alpha_2\beta_2$ ).  $\alpha$  thalassemias result from reduced synthesis of  $\alpha$ -globin chains, while  $\beta$  thalassemias result from reduced production of  $\beta$ -globin chains. Therefore,  $\alpha$  thalassemias are associated with a relative excess production of non- $\alpha$ -globin chains, while  $\beta$  thalassemias are associated with a relative excess production of  $\alpha$ -globin chains. Non- $\alpha$ -globin chains are  $\gamma$ -globin chains (which form  $\gamma$  tetramers called hemoglobin Bart's) in the fetus, but are  $\beta$ -globin chains (which form  $\beta$  tetramers called hemoglobin H) in the adult. Most of the  $\alpha$  thalassemias result from deletions of one or more of the total of four  $\alpha$ -globin genes, while  $\beta$  thalassemias result from point mutations involving the  $\beta$ -globin gene. There are two  $\alpha$ -globin genes on each chromosome 16, and the normal genotype is  $\alpha\alpha$ . On each chromosome either or both of the  $\alpha$  genes can be deleted. Deletion of both genes ( $-\alpha-$ ) is called  $\alpha$  thal 1. This genotype is found in individuals in Southeast Asia and the Mediterranean. In contrast, deletion of only one  $\alpha$  gene on a chromosome ( $-\alpha/$ ) is called  $\alpha$  thal 2 and is found in Africans. The severity of  $\alpha$  thalassemia depends on the number of  $\alpha$  genes deleted. Deletions of only one gene ( $\alpha/\alpha$ ) results in a silent carrier. These patients are completely asymptomatic and all laboratory tests are normal. This clinical state can only be inferred from examination of a pedigree. Deletion of two  $\alpha$  genes results in  $\alpha$  thal trait. There are two possibilities for deletion of two  $\alpha$  genes: the deletions may be on the same chromosome ( $-\alpha/\alpha$ , which is called the cis type) or the deletions may be on different chromosomes ( $\alpha/-\alpha$ , which is called the trans type). The former, which is also called heterozygous  $\alpha$  thal 1, is more common in Asians, while the latter, which is also called  $\alpha$  thal 2, is more common in Africans. Clinically this is quite important because the off-spring of parents with the trans deletions cannot develop H disease or hydrops. Deletion of three  $\alpha$  genes ( $-\alpha/-\alpha$ ) is called hemoglobin H disease. This name results from the fact that excess  $\beta$  chains postnatally form aggregates of  $\beta$  tetramers, which are called hemoglobin H. These aggregates form Heinz bodies, which can be seen with crystal blue stain. The most severe form of  $\alpha$  thalassemia, hydrops fetalis, results from deletion of all four alpha genes ( $-\alpha/-\alpha$ ). In this disease, which is lethal in utero, no  $\alpha$  chains are produced. Staining of the erythrocytes with a supravital stain demonstrates numerous intracytoplasmic inclusions within the red cells, which are aggregates of hemoglobin Bart's ( $\gamma_4$ ).

3. The answer is d.  $\beta$  thalassemias result from reduced production of  $\beta$ -globin chains, which results in a relative excess production of  $\alpha$ -globin chains. Most of the  $\beta$  thalassemias result from point mutations involving the  $\beta$ -globin gene. The amount of  $\beta$ -globin produced depends upon the location of the point mutation. Promoter region mutations result in decreased production of  $\beta$ -globin. This is called  $\beta^+$  thalassemia. Chain terminator mutations generally produce no functional  $\beta$ -globin. This is called  $\beta^0$  thalassemia. Splicing mutations may result in either  $\beta^0$  or  $\beta^+$  thalassemia. In patients with  $\beta$  thalassemia, a deficiency of  $\beta$ -globins causes a deficiency of hemoglobins that have  $\beta$ -globin chains, and at the same time there is an increase in hemoglobins that do not have  $\beta$ -globin chains (due to the excess  $\alpha$  chains present). These hemoglobins include hemoglobin A2 ( $\alpha_2\delta_2$ ) and haemoglobin F ( $\alpha_2\delta_2$ ). The most severe clinical form of  $\beta$  thalassemia is Cooley's anemia ( $\beta$  thal major), which is characterized by severe, transfusiondependent anemia. Because of the need for repeated transfusions, over time these patients develop iron accumulation that leads to the formation of hemochromatosis. Indeed, congestive heart failure due to iron deposition within the heart is the major cause of death. Individuals with  $\beta$  thal major



have increased reticulocytes, increased hemoglobin A2, and markedly increased hemoglobin F (90%). In these patients, increased  $\alpha$  chains produce intramedullary destruction (“ineffective erythropoiesis”). The resultant increased red marrow produces a “crew-cut” x-ray appearance of the skull and enlarges the maxilla.

### **Recommended literature:**

#### **A. Main:**

1. “Harrison's principles of internal medicine”, Editors: Dan L. Longo, Dennis L. Kasper, J. Larry Jameson, Anthony S. Fauci, Stephen L. Hauser, Joseph Loscalzo, 18th ed. McGraw Hill. – 2012, 1-2 volumes. CURRENT Medical Diagnosis and Treatment 2012, Fifty-First Edition (LANGE CURRENT Series) by Stephen McPhee, Maxine Papadakis and Michael W. Rabow (Paperback - Sep 12, 2011)
2. Davidson's Principles and Practice of Medicine: With STUDENT CONSULT Online Access, 21e (Principles & Practice of Medicine (Davidson's)) by Nicki R. Colledge BSc FRCP(Ed), Brian R. Walker BSc MD FRCP(Ed) and Stuart H. Ralston MB ChB MD FRCP FMedSci FRSE (Paperback - Mar 11, 2010) Kumar and Clark's Clinical Medicine, 7e (Kumar, Kumar and Clark's Clinical Medicine) by Parveen J. Kumar (Paperback - Jul 2, 2009)
3. 1000 Questions and Answers from Kumar & Clark's Clinical Medicine, 2e [Paperback] Parveen Kumar CBE BSc MD FRCP FRCP(Edin) (Editor), Michael L Clark MD FRCP (Editor)
4. Differential Diagnosis in Internal Medicine: From Symptom to Diagnosis by Walter Siegenthaler (Mar 21, 2007)
5. Symptom to Diagnosis: An Evidence Based Guide, Second Edition (LANGE Clinical Medicine) by Scott D. C. Stern (Sep 16, 2009)
6. CURRENT Diagnosis and Treatment Emergency Medicine, Seventh Edition (LANGE CURRENT Series) by C. Keith Stone (May 23, 2011)
7. Harrison's Gastroenterology and Hepatology by Dan Longo and Anthony Fauci (May 3, 2010)
8. Mayo Clinic Gastroenterology and Hepatology Board Review (Mayo Clinic Scientific Press) by Stephen Hauser (Jun 23, 2011)
9. Clinical Nephrology 2012 (The Clinical Medicine Series) by M.D., C. G. Weber (Sep 19, 2011) - Kindle eBook
10. Goldman's Cecil medicine / [edited by] Lee Goldman, Andrew I. Schafer.—24th ed. Elsevier Sanders. Rev. ed. of: Cecil medicine. 23rd ed. – 2012. p.
11. Sonographer's Handbook of Diagnostic Ultrasound by Jason R. Young M.D. (Feb 23, 2011)

#### **Additional literature:**

1. Kovalyova O.M., Asheulova T.V. Propedeutics to internal medicine. Part 1, Diagnostics. Vinnytsya, Nova Knyha, 2006, 424 p

### **Answers**

1. c
2. a