

**MINISTRY OF HEALTHCARE OF UKRAINE
HSEEU "Ukrainian Medical Stomatological Academy"**

"Approved"
at the meeting of internal
medicine №1 department
Head of Department
Prof. Skrypnyk I.M.

Protocol № 2 from 15.09.2016

**GUIDELINES
FOR STUDENTS
INDEPENDENT WORK
IN THE PRACTICAL CLASSES PREPARING**

<i>Academic discipline</i>	Internal medicine
<i>Module</i>	Basics of Internal Medicine
<i>Content module</i>	Fundamentals of diagnostics, treatment and prevention of gastroenterological diseases
<i>Study subject</i>	Liver cirrhosis.
<i>Course</i>	IV
<i>Faculty</i>	of foreign students training

1. Relevance of the topic: Liver cirrhosis is a diffuse process characterized by fibrosis and conversion of normal architecture to structurally abnormal nodules. These “regenerative” nodules lack normal lobular organization and are surrounded by fibrous tissue. The process involves the whole liver and is essentially irreversible. According to the World Health Organization, about 800,000 people die of cirrhosis annually. Because chronic liver disease affects people in their most productive years of life, it has a significant impact on the economy as a result of premature death, illness, and disability. The natural history of cirrhosis is characterized by an initial phase, termed compensated cirrhosis, followed by a rapidly progressive phase marked by the development of complications of portal hypertension or liver dysfunction (or both), termed decompensated cirrhosis.

2. The main goal: To be able to assess the typical clinical picture of liver cirrhosis, to determine tactics of treatment and prophylaxis.

Specific goals:

- To select the information indicating the presence of liver cirrhosis in a patient from the data history;
- To create a scheme of diagnostic search;
- To identify the signs of liver cirrhosis in an objective study of the patient (general examination, palpation, percussion, auscultation);
- To analyze and interpret the changes in the results of the laboratory and instrumental methods of investigation, depending on the course of the disease;
- To formulate and justify a preliminary diagnosis of liver cirrhosis according to classification;
- To conduct differential diagnostics of diseases with the similar clinical picture;
- To develop a strategy of treatment depending on the disease and the existing complications;
- To provide medical care;
- To assess the patient's prognosis and to propose a plan of preventive actions;
- To apply deontological communication skills with patients.

3. Basic knowledge, abilities, skills (interdisciplinary integration)

Discipline	To know	To be able to
Anatomy	The structure of the gastrointestinal tract, liver, blood supply, innervation	
Histology	The structure of liver in health and disease	To interpret results of liver biopsy
Regional anatomy	Interposition of the gastrointestinal organs	
Physiology	Indicators of gastrointestinal tract function, its value	To determine the function of gastrointestinal organs
Morbid anatomy	Changes in the structure of liver in chronic hepatitis	
Propaedeutic therapy	Symptomatology of chronic hepatitis and complications	Conduct an objective examination of the patient, analyze the clinical and laboratory results
Pharmacology	The mechanism of action,	Prescribe the drugs of these groups

	indications and contraindications for the hepatoprotective drugs, antiviral drugs, diuretics, β -blockers, corticosteroids, statins, vitamins	
--	---	--

4. Do the tasks for independent work during preparation for classes.

4.1. The list of key terms, parameters, characteristics:

Term	Definition
Liver cirrhosis	is a diffuse process characterized by fibrosis and conversion of normal architecture to structurally abnormal nodules.
Syndrome of cytolysis	complex of symptoms that includes clinical signs and elevated liver intracellular enzymes (AST, ALT, GGT, LDH) in blood that indicates on necrosis.
Cryptogenic cirrhosis	is a cirrhosis of unknown etiology when all the causes have been investigated and excluded.
Ascites	is an accumulation of fluid in the abdominal cavity.
Hepatic encephalopathy	is a spectrum of neuropsychiatric abnormalities in patients with liver dysfunction, after exclusion of brain disease that is characterized by personality changes, intellectual impairment, and a depressed level of consciousness.

4.2. Theoretical questions for the lesson:

1. Give the definitions of liver cirrhosis.
2. Specify the etiological and risk factors for liver cirrhosis.
3. The pathophysiological mechanisms of liver cirrhosis.
4. Diagnostic criteria of liver cirrhosis.
5. What are the laboratory characteristics of liver cirrhosis and its stages?
6. Modern classification of liver cirrhosis.
7. Specify the principles and features of liver cirrhosis pharmacotherapy according to etiology and modern recommendations.
8. What lifestyle modifications should be recommended for patients with liver cirrhosis?

4.3. Practical tasks that are performed in class:

1. The two main consequences of cirrhosis are:
 - 1) Encephalopathy and splenomegaly
 - 2) Hepatomegaly and splenomegaly
 - 3) Hepatocellular carcinoma and ascites
 - 4) Anaemia and thrombocytopenia
 - 5) **Portal hypertension and liver insufficiency**
2. What preparations will be the most effective in viral cirrhosis?
 - 1) Antibiotics
 - 2) Glucocorticoids

3) Hepatoprotectors

4) Alpha-interferon

5) Lactulose

3. What method of diagnostics will be the most informative in detecting liver cirrhosis?

1) Proteinogram

2) Markers of viral hepatitis

3) Violation of cellular immunity

4) Activity of cytolysis (AST, ALT)

5) Puncture biopsy of liver

4. To reduce portal pressure can be used:

1) Diuretics

2) Antibiotics

3) Nonselective beta-blockers

4) Antifibrotics

5) Lactulose

5. What laboratory test can give the most precise characteristic of cytolysis degree?

1) Transaminase test

2) Weltman's coagulation test

3) Takata-Ara test

4) Prothrombin test

5) Test for whole protein

Topic Content

LIVER CIRRHOSIS

Definition. Liver cirrhosis is a diffuse process characterized by fibrosis and conversion of normal architecture to structurally abnormal nodules. These "regenerative" nodules lack normal lobular organization and are surrounded by fibrous tissue. The process involves the whole liver and is essentially irreversible.

Classification. Liver cirrhosis can be classified according to etiology (see etiological factors below).

Although cirrhosis is histologically an "all or nothing" diagnosis, clinically it can be classified by its status as compensated or decompensated. Decompensated cirrhosis is defined by the presence of ascites, variceal bleeding, encephalopathy, or jaundice, which are complications that result from the main consequences of cirrhosis: portal hypertension and liver insufficiency.

When all the causes have been investigated and excluded, cirrhosis is considered "cryptogenic".

According to morphological features: micronodular (nodules 1-3 mm), macronodular (nodules >3mm), mixed, septal.

There are two most commonly used scoring systems in cirrhosis: Child-Pugh (range, 5-15) and model of end-stage liver disease (MELD) score (range, 6-40).

MELD score: $[0.957 \times \text{LN (creatinine in mg/dL)} + 0.378 \times \text{LN (bilirubin in mg/dL)} + 1.12 \times \text{LN (INR)} + 0.643] \times 10$. Where LN is natural logarithm.

Child-Pugh classification: Child A - score of 5-6; Child B - score of 7-9; Child C - score of 10-15 (table 1).

TABLE 1.

Parameters	Points Ascribed		
	1	2	3
Ascites	None	Grade 1-2 (or easy to treat)	Grade 3-4 (or refractory)
Hepatic encephalopathy	None	Grade 1-2 (or induced by a precipitant)	Grade 3-4 (or spontaneous)
Bilirubin (mg/dL) (μ mol/L)	<2 <34	2-3 34-51	>3 >51
Albumin (g/dL) (g/L)	>3.5 >35	2.8-3.5 30-35	<2.8 <30
Prothrombin time (seconds > control) or INR (international normalized ratio)	<4 <1.7	4-6 1.7-2.3	>6 >2.3

Epidemiology. Because many patients with cirrhosis are asymptomatic until decompensation occurs, it is very difficult to assess the real prevalence and incidence of cirrhosis in the general population. The prevalence of chronic liver disease or cirrhosis worldwide is estimated to be 100 (range, 25 to 400) per 100,000 subjects, but it varies widely by country and by region. According to the World Health Organization, about 800,000 people die of cirrhosis annually. Because chronic liver disease affects people in their most productive years of life, it has a significant impact on the economy as a result of premature death, illness, and disability.

Etiological factors. Any chronic liver disease can lead to cirrhosis. Chronic viral hepatitis C and alcoholic liver disease are the most common causes of cirrhosis, followed by nonalcoholic fatty liver disease and chronic hepatitis B.

However, the many other causes of cirrhosis include cholestatic and autoimmune liver diseases such as primary biliary cirrhosis, primary sclerosing cholangitis, autoimmune hepatitis, and metabolic diseases such as hemochromatosis, Wilson's disease, and α 1-antitrypsin deficiency.

It is important to mention that although the entity termed primary biliary cirrhosis assumes the presence of cirrhosis, this term is actually misleading. Primary biliary cirrhosis is an immune-mediated cholestatic chronic liver disease that is characterized by progressive destruction of intrahepatic bile ducts and progresses over time from an initial stage in which fibrosis is minimal (stage 1) to a final stage in which there is well-established cirrhosis (stage 4).

Toxines (including such medicines as amiodarone, methotrexat), hepatic venous outflow obstruction (Budd-Chiari syndrome, veno-occlusive disease, right-sided heart failure) also are the common causes of liver cirrhosis.

Pathogenesis. The key pathogenic feature underlying liver fibrosis and cirrhosis is activation of hepatic stellate cells. Hepatic stellate cells, which are known as Ito cells or perisinusoidal cells, are located in the space of Disse between hepatocytes and sinusoidal endothelial cells. Normally, hepatic stellate cells are quiescent and serve as the main storage site for retinoids (vitamin A). In response to injury, hepatic stellate cells become activated, as a result of which they lose their vitamin A deposits, proliferate, develop a prominent rough endoplasmic reticulum, and secrete extracellular matrix (collagen types I and III, sulfated proteoglycans, and glycoproteins). Additionally, they become contractile hepatic myofibroblasts. Unlike other capillaries, normal hepatic sinusoids lack a basement membrane. The sinusoidal endothelial cells themselves contain large fenestrae (100 to 200 nm in diameter) that allow the passage of large molecules with molecular weights up to 250,000. Collagen deposition in the space of Disse, as occurs in cirrhosis, leads to defenestration of the sinusoidal endothelial cells ("capillarization" of

the sinusoids), thereby altering exchange between plasma and hepatocytes and resulting in a decreased sinusoidal diameter that is further exacerbated by the contraction of stellate cells.

The two main consequences of cirrhosis are portal hypertension, with the accompanying hyperdynamic circulatory state, and liver insufficiency.

The development of varices and ascites is a direct consequence of portal hypertension and the hyperdynamic circulatory state, whereas jaundice occurs as a result of an inability of the liver to excrete bilirubin (i.e., liver insufficiency).

Encephalopathy is the result of both portal hypertension and liver insufficiency.

Ascites, in turn, can become complicated by infection, which is called spontaneous bacterial peritonitis, and by functional renal failure, which is called hepatorenal syndrome.

Portal Hypertension and the Hyperdynamic Circulatory State. In cirrhosis, portal hypertension results from both an increase in resistance to portal flow and an increase in portal venous inflow. The initial mechanism is increased sinusoidal vascular resistance secondary to deposition of fibrous tissue and subsequent compression by regenerative nodules (fixed component) and active vasoconstriction (functional component), which is amenable to the action of vasodilators such as nitroprusside and is caused by a deficiency in intrahepatic nitric oxide (NO), as well as enhanced activity of vasoconstrictors. Early in the portal hypertensive process, the spleen grows and sequesters platelets and other formed blood cells, thereby leading to hypersplenism. In addition, vessels that normally drain into the portal system, such as the coronary vein, reverse their flow and shunt blood away from the portal system to the systemic circulation. These portosystemic collaterals are insufficient to decompress the portal venous system and offer additional resistance to portal flow.

As collaterals develop, an increase in portal blood inflow maintains the portal hypertensive state as a result of splanchnic vasodilation, which in turn is secondary to increased production of NO. Thus, the paradox in portal hypertension is that a deficiency of NO in the intrahepatic vasculature leads to vasoconstriction and increased resistance, whereas overproduction of NO in the extrahepatic circulation leads to vasodilation and increased flow.

Varices and Variceal Hemorrhage. The complication of cirrhosis that results most directly from portal hypertension is the development of portal-systemic collaterals, the most relevant of which are those that form through dilation of the coronary and gastric veins and constitute gastroesophageal varices. The initial formation of esophageal collaterals depends on a threshold portal pressure, clinically established by a hepatic venous pressure gradient of 10 to 12 mm Hg, below which varices do not develop. Development of a hyperdynamic circulatory state leads to further dilation and growth of varices and eventually to their rupture and variceal hemorrhage, one of the most dreaded complications of portal hypertension.

Ascites and Hepatorenal Syndrome. Ascites in cirrhosis is secondary to sinusoidal hypertension and retention of sodium. Cirrhosis leads to sinusoidal hypertension by blocking hepatic venous outflow both anatomically by fibrosis and regenerative nodules and functionally by increased postsinusoidal vascular tone. Similar to the formation of esophageal varices, a threshold hepatic venous pressure gradient of 12 mm Hg is needed for the formation of ascites. In addition, retention of sodium replenishes the intravascular volume and allows the continuous formation of ascites.

With progression of cirrhosis and portal hypertension, vasodilation is more pronounced, thereby leading to further activation of the renin-angiotensin-aldosterone and sympathetic nervous systems and resulting in further sodium retention (refractory ascites), water retention (hyponatremia), and renal vasoconstriction (hepatorenal syndrome).

Spontaneous Bacterial Peritonitis. Spontaneous bacterial peritonitis, an infection of ascitic fluid, occurs in the absence of perforation of a hollow viscus or an intra-abdominal

inflammatory focus such as an abscess, acute pancreatitis, or cholecystitis. Bacterial translocation, or the migration of bacteria from the intestinal lumen to mesenteric lymph nodes and other extraintestinal sites, is the main mechanism implicated in spontaneous bacterial peritonitis. Impaired local and systemic immune defenses are a major element in promoting bacterial translocation and, together with shunting of blood away from the hepatic Kupffer cells through portosystemic collaterals, allow a transient bacteremia to become more prolonged, thereby colonizing ascitic fluid. Spontaneous bacterial peritonitis occurs in patients with reduced ascites defense mechanisms, such as a low complement level in ascitic fluid. Another factor that promotes bacterial translocation in cirrhosis is bacterial overgrowth attributed to a decrease in small bowel motility and intestinal transit time.

Jaundice. Jaundice in cirrhosis is a reflection of the inability of the liver to excrete bilirubin and is therefore the result of liver insufficiency. However, in cholestatic diseases leading to cirrhosis (e.g., primary biliary cirrhosis, primary sclerosing cholangitis, vanishing bile duct syndrome), jaundice is more likely due to biliary damage than liver insufficiency. Other indicators of liver insufficiency, such as the prothrombin time or the presence of encephalopathy, help determine the most likely contributor to hyperbilirubinemia.

Encephalopathy. Ammonia, a toxin normally removed by the liver, plays a key role in the pathogenesis of hepatic encephalopathy. In cirrhosis, ammonia accumulates in the systemic circulation because of shunting of blood through portosystemic collaterals and decreased liver metabolism (i.e., liver insufficiency).

The presence of large amounts of ammonia in the brain damages supporting brain cells or astrocytes and leads to structural changes characteristic of hepatic encephalopathy (Alzheimer's type II astrocytosis). Ammonia results in upregulation of astrocytic peripheral-type benzodiazepine receptors, the most potent stimulants of neurosteroid production. Neurosteroids are the major modulators of γ -aminobutyric acid, which results in cortical depression and hepatic encephalopathy. Other toxins, such as manganese, also accumulate in the brain, particularly the globus pallidus, where they lead to impaired motor function. Other yet-to-be-elucidated toxins may also be involved in the pathogenesis of encephalopathy. There are three types of encephalopathy depending on the underlying cause: Type A (acute) – associated with acute liver failure; Type B (bypass) – associated with porto-systemic shunting, the waste is not metabolized because the blood bypasses the liver; Type C (cirrhosis) – associated with cirrhosis and chronic deterioration of liver function. This type is subdivided in episodic, persistent, and minimal. West-Haven criteria are used to estimate the stage of encephalopathy. Latent encephalopathy can be detected by number connection test and line tracing test.

West Haven Criteria for Semi-quantitative Grading of Mental Status	
Grade 1	Trivial lack of awareness Euphoria or anxiety Shortened attention span Impaired performance of addition
Grade 2	Lethargy or apathy Minimal disorientation for time or place Subtle personality change Inappropriate behavior Impaired performance of subtraction
Grade 3	Somnolence to semi-stupor, but responsive to verbal stimuli Confusion Gross disorientation
Grade 4	Coma (unresponsive to verbal or noxious stimuli)

Cardiopulmonary Complications. The hyperdynamic circulatory state eventually results in high-output heart failure with decreased peripheral utilization of oxygen, a complication that has been referred to as cirrhotic cardiomyopathy. Vasodilation at the level of the pulmonary circulation leads to arterial hypoxemia, the hallmark of hepatopulmonary syndrome. Normal pulmonary capillaries are 8 μm in diameter, and red blood cells (slightly less than 8 μm) pass through them one cell at a time, thereby facilitating oxygenation. In hepatopulmonary syndrome, the pulmonary capillaries are dilated up to 500 μm , so passage of red cells through the pulmonary capillaries may be many cells thick. As a result, a large number of red cells are not oxygenated, which causes the equivalent of a right-to-left shunt. Conversely, portopulmonary hypertension occurs when the pulmonary bed is exposed to vasoconstrictive substances that may be produced in the splanchnic circulation and bypass metabolism by the liver; the initial result is reversible pulmonary hypertension. However, because these factors result in endothelial proliferation, vasoconstriction, in situ thrombosis, and obliteration of vessels, irreversible pulmonary hypertension ensues.

Clinical features. The clinical manifestations of cirrhosis range widely, depending on the stage of cirrhosis, from an asymptomatic patient with no signs of chronic liver disease to a patient who is confused and jaundiced and has severe muscle wasting and ascites. The natural history of cirrhosis is characterized by an initial phase, termed compensated cirrhosis, followed by a rapidly progressive phase marked by the development of complications of portal hypertension or liver dysfunction (or both), termed decompensated cirrhosis.

In the compensated phase, portal pressure may be normal or below the threshold level identified for the development of varices or ascites. Nonspecific fatigue, decreased libido, or sleep disturbances may be the only complaints. In this stage, cirrhosis is mostly asymptomatic and is diagnosed either during the evaluation of chronic liver disease or fortuitously during routine physical examination, biochemical testing, imaging for other reasons, endoscopy showing gastroesophageal varices, or abdominal surgery in which a nodular liver is detected. Nonbleeding gastroesophageal varices are asymptomatic, and their presence (without bleeding) does not denote decompensation.

As the disease progresses, portal pressure increases and liver function decreases, thereby resulting in the development of ascites, portal hypertensive gastrointestinal (GI) bleeding, encephalopathy, and jaundice. The development of any of these complications marks the transition from a compensated to a decompensated phase. At this stage, there are signs of decompensation: ascites, variceal hemorrhage, jaundice, hepatic encephalopathy, or any combination of these findings. Bleeding from gastroesophageal varices can be manifested as overt hematemesis or melena, or both. The most frequent symptoms associated with ascites are increased abdominal girth, which is often described by the patient as tightness of the belt or garments around the waist, and recent weight gain. When present in small to moderate amounts, ascites can be identified on examination by bulging flanks, flank dullness, and shifting dullness. Patients with hepatorenal syndrome usually have tense ascites that responds poorly to diuretics, but no specific symptoms or signs typify this entity.

The most frequent clinical manifestations of spontaneous bacterial peritonitis are fever, jaundice, and abdominal pain. On physical examination, there is typically abdominal tenderness, with or without rebound tenderness, or ileus (or both). Hepatic encephalopathy, which is the neuropsychiatric manifestation of cirrhosis, occurs at a rate of approximately 2 to 3% per year. Clinically, it is characterized by alterations in consciousness and behavior ranging from inversion of the sleep-wake pattern and forgetfulness (stage 1); to confusion, bizarre behavior, and disorientation (stage 2); to lethargy and profound disorientation (stage 3); to coma (stage 4). On physical examination, early stages may demonstrate only a distal tremor, but the hallmark of

hepatic encephalopathy is the presence of asterixis. Additionally, patients with hepatic encephalopathy may have sweet-smelling breath, a characteristic termed fetor hepaticus.

Hepatopulmonary syndrome is associated with exertional dyspnea, which can lead to extreme debilitation. Clubbing of the fingers, cyanosis, and vascular spiders may be seen on physical examination. Portopulmonary hypertension is manifested as exertional dyspnea, syncope, and chest pain. On examination, an accentuated second sound and right ventricular heave are prominent.

The median time to decompensation, or the time at which half the patients with compensated cirrhosis will become decompensated, is about 6 years.

Progression to death may be accelerated by the development of complications such as recurrent GI bleeding, renal impairment (refractory ascites, hepatorenal syndrome), hepatopulmonary syndrome, and sepsis (spontaneous bacterial peritonitis).

Diagnosis. The diagnosis of cirrhosis should be considered in any patient with chronic liver disease. In asymptomatic patients with compensated cirrhosis, typical signs of cirrhosis may not be present, and the diagnosis may often require histologic confirmation by liver biopsy, which is the “gold standard” for the diagnosis of cirrhosis.

Physical Examination. On physical examination, stigmata of cirrhosis consist of muscle atrophy, mainly involving the bitemporal muscle regions and the thenar and hypothenar eminences; spider angiomas, mostly on the trunk, face, and upper limbs; and palmar erythema involving the thenar and the hypothenar eminences and the tips of the fingers. Although muscular atrophy is a marker of liver insufficiency, spider angiomas and palmar erythema are markers of vasodilation and a hyperdynamic circulation. Males may have hair loss on the chest and abdomen, gynecomastia, and testicular atrophy. Petechiae and ecchymoses may be present as a result of thrombocytopenia or a prolonged prothrombin time. Dupuytren’s contracture, which is a thickening of the palmar fascia, occurs mostly in alcoholic cirrhosis.

A pathognomonic feature of cirrhosis is the finding on abdominal examination of a small right liver lobe, with a span of less than 7 cm on percussion, and a palpable left lobe that is nodular with increased consistency. Splenomegaly may also be present and is indicative of portal hypertension. Collateral circulation on the abdominal wall (caput medusae) may also develop as a consequence of portal hypertension.

Absence of any of the aforementioned physical findings does not exclude cirrhosis.

Laboratory Tests. Laboratory test results suggestive of cirrhosis include even subtle abnormalities in serum levels of albumin or bilirubin or elevation of the international normalized ratio.

The most sensitive and specific laboratory finding suggestive of cirrhosis in the setting of chronic liver disease is a low platelet count ($<150,000/\text{mm}^3$), which occurs as a result of portal hypertension and hypersplenism.

Other serum markers that are often abnormal include levels of aspartate aminotransferase (AST), alanine aminotransferase (ALT), γ -glutamyl transpeptidase (GGT), hyaluronic acid, α_2 macroglobulin, haptoglobin, tissue metalloproteinase inhibitor I, and apolipoprotein A. Decreased synthetic liver function is observed in biochemical analysis and coagulogram according to failed function.

Imaging Studies. Confirmatory imaging tests include computed tomography, ultrasound, and magnetic resonance imaging. Findings consistent with cirrhosis include a nodular contour of the liver, a small liver with or without hypertrophy of the left or caudate lobe, splenomegaly, and in particular, identification of intraabdominal collateral vessels indicative of portal hypertension.

Transient elastography, a new noninvasive technique based on ultrasound wave propagation, measures liver stiffness and appears to be useful in the diagnosis of cirrhosis.

Typical findings on any of these imaging studies, together with a compatible clinical picture, are indicative of the presence of cirrhosis. A liver biopsy then would not be required unless the degree of inflammation or other features require investigation. In decompensated cirrhosis, detection of ascites, variceal bleeding, or encephalopathy in the setting of chronic liver disease essentially establishes the diagnosis of cirrhosis, so a liver biopsy is not necessary to establish the diagnosis.

Portal Pressure Measurements. Direct measurements of portal pressure involve catheterization of the portal vein, are cumbersome, and may be associated with complications. Hepatic vein catheterization with measurement of wedged and free pressure is the simplest, safest, most reproducible, and most widely used method to indirectly measure portal pressure. Portal pressure measurements are expressed as the hepatic venous pressure gradient: the gradient between wedged hepatic venous pressure, which is a measure of sinusoidal pressure, and free hepatic or inferior vena cava pressure, which is used as an internal zero reference point. In a patient with clinical evidence of portal hypertension (e.g., varices), the hepatic venous pressure gradient is useful in the differential diagnosis of the cause of portal hypertension: it will be normal (3 to 5 mm Hg) in prehepatic causes of portal hypertension, such as portal vein thrombosis, and in intrahepatic but presinusoidal causes, such as schistosomiasis, but will be abnormal (≥ 6 mm Hg) in sinusoidal causes of portal hypertension, such as cirrhosis, and in postsinusoidal causes, such as veno-occlusive disease. A hepatic venous pressure gradient of 10 mm Hg or greater ("clinically significant" portal hypertension) predicts the development of complications of portal hypertension, and its reduction on pharmacologic therapy predicts a favorable outcome in patients with cirrhosis.

Other tests. Upper GI endoscopy remains the main method for diagnosing varices and variceal hemorrhage. Varices are classified as small (straight, minimally elevated veins above the esophageal mucosal surface), medium (tortuous veins occupying less than one third of the esophageal lumen), or large (occupying more than one third of the esophageal lumen).

The initial, most cost-effective, and least invasive method to confirm the presence of ascites is abdominal ultrasonography. Diagnostic paracentesis is a safe procedure that should be performed in every patient with new-onset ascites, even in those with coagulopathy. Ultrasound guidance should be used in patients in whom percussion cannot locate the ascites or in whom a first paracentesis attempt does not yield fluid. The fluid in a patient with new-onset ascites should always be evaluated for albumin (with simultaneous estimation of serum albumin), total protein, polymorphonuclear (PMN) blood cell count, bacteriologic cultures, and cytology. The diagnosis of hepatic encephalopathy is clinical and based on the history and physical examination showing alterations in consciousness and behavior, as well as the presence of asterixis. Ammonia levels are unreliable, and there is poor correlation between the stage of hepatic encephalopathy and ammonia blood levels. Therefore, measurements of ammonia are not useful. Psychometric tests and an electroencephalogram are typically used in research but are not useful for clinical diagnosis.

Complications. Complications of cirrhosis result from portal hypertension or liver insufficiency. Varices and variceal hemorrhage are a direct consequence of portal hypertension. Ascites results from sinusoidal portal hypertension and can be complicated by infection (spontaneous bacterial peritonitis) or renal dysfunction (hepatorenal syndrome). Hepatic encephalopathy results from portosystemic shunting (i.e., portal hypertension) and liver insufficiency. Jaundice results solely from liver insufficiency. The development of hepatocellular carcinoma may accelerate the course of the disease at any stage. Anaemia, thrombocytopenia and coagulopathy are the common complications in such patients.

Differential diagnosis. The main goal in differential diagnosis of cirrhosis is to determine the reason of it. Thus, markers of viral hepatitis should be identified.

	Antigen(s)	Antibodies	Remarks
HCV	C100-3 C33c C22-3 NS5	Anti-HCV	Bloodborne agent, formerly labeled non-A, non-B hepatitis Acute diagnosis: anti-HCV (C33c, C22-3, NS5), HCV RNA Chronic diagnosis: anti-HCV (C100-3, C33c, C223, NS5) and HCV RNA; cytoplasmic location in hepatocytes
HBV	HBsAg HBcAg HBeAg HBcAg HBeAg HBsAg	Anti-HBs Anti-HBc Anti-HBe Anti-HBc Anti-HBe Anti-HBs	Bloodborne virus; carrier state Acute diagnosis: HBsAg, IgM anti-HBc Chronic diagnosis: IgG anti-HBc, HBsAg Markers of replication: HBeAg, HBV DNA Liver, lymphocytes, other organs Nucleocapsid contains DNA and DNA polymerase; present in hepatocyte nucleus; HBcAg does not circulate; HBeAg (soluble, nonparticulate) and HBV DNA circulate—correlate with infectivity and complete virions HBsAg detectable in >95% of patients with acute hepatitis B; found in serum, body fluids, hepatocyte cytoplasm; anti-HBs appears following infection—protective

			antibody
HDV	HBsAg HDAg	Anti-HBs Anti-HDV	Defective RNA virus, requires helper function of HBV (hepadnaviruses); HDV antigen (HDAg) present in hepatocyte nucleus Diagnosis: anti-HDV, HDV RNA; HBV/HDV co-infection—IgM anti-HBc and anti-HDV; HDV superinfection—IgG anti-HBc and anti-HDV

Autoimmune and metabolic disorders, influence of alcohol, drugs and other toxins have to be excluded.

The most common cause of ascites is cirrhosis, which accounts for 80% of cases. Peritoneal malignancy (e.g., peritoneal metastases from GI tumors or ovarian cancer), heart failure, and peritoneal tuberculosis together account for another 15% of cases. The serum-ascites albumin gradient and ascites protein levels are useful in the differential diagnosis of ascites. The serum-ascites albumin gradient correlates with sinusoidal pressure and will therefore be elevated (>1.1 g/dL) in patients in whom the source of ascites is the hepatic sinusoid (e.g., cirrhosis or cardiac ascites). Protein levels in ascitic fluid are an indirect marker of the integrity of the hepatic sinusoids: normal sinusoids are permeable structures that “leak” protein, whereas sinusoids in cirrhosis are “capillarized” and do not leak as much protein. The three main causes of ascites—cirrhosis, peritoneal malignancy or tuberculosis, and heart failure— can easily be distinguished by combining the results of both the serum-ascites albumin gradient and ascites total protein content. Cirrhotic ascites typically has a high serum-ascites albumin gradient and low protein, cardiac ascites has a high serum-ascites albumin gradient and high protein, and ascites secondary to peritoneal malignancy typically has a low serum-ascites albumin gradient and high protein.

Cardiac etiology should be certainly excluded.

Treatment. Treatment of cirrhosis should ideally be aimed at interrupting or reversing fibrosis. However, antifibrotic drugs have not been shown to reverse fibrosis consistently or improve outcomes in cirrhotic patients. Treatment of compensated cirrhosis is currently directed at preventing the development of decompensation by treating the underlying liver disease (e.g., antiviral therapy for hepatitis C or B) to reduce fibrosis and prevent decompensation; avoiding factors that could worsen liver disease, such as alcohol and hepatotoxic drugs (Nonsteroidal anti-inflammatory drugs, Isoniazid, Valproic acid, Erythromycin, Amoxicillin-clavulanate, Ketoconazole, Chlorpromazine, Ezetimibe etc.); and screening for varices (to prevent variceal hemorrhage) and for hepatocellular carcinoma (to treat at an early stage).

- Prednisone and azathioprine - For autoimmune hepatitis;
- Interferon and other antiviral agents - For hepatitis B and C;
- Phlebotomy - For hemochromatosis;
- Ursodeoxycholic acid - For primary biliary cirrhosis;
- Trientine and zinc - For Wilson disease.

Treatment of decompensated cirrhosis focuses on specific decompensating events and the option of liver transplantation.

- Hepatorenal syndrome - patients with early hepatorenal syndrome may be salvaged by aggressive expansion of intravascular volume with albumin and fresh frozen plasma and by avoidance of diuretics.

Nephrotoxic medications, including aminoglycoside antibiotics, should be avoided in patients with cirrhosis. Patients with early hepatorenal syndrome may be salvaged by aggressive expansion of intravascular volume with albumin and fresh frozen plasma and by avoidance of diuretics. The use of renal-dose dopamine is not effective.

- Hepatic encephalopathy - pharmacologic treatment includes the administration of lactulose and antibiotics.

The main treatment for encephalopathy is lactulose syrup. This nonabsorbable disaccharide stimulates the passage of ammonia from tissues into the gut lumen and inhibits intestinal ammonia production. Initial lactulose dosing is 30 mL orally once or twice daily. Dosing is increased until the patient has 2-4 loose stools per day. Dosing should be reduced if the patient complains of diarrhea, abdominal cramping, or bloating. Higher doses of lactulose may be administered via either a nasogastric or rectal tube to hospitalized patients with severe encephalopathy.

Antibiotics serve as second-line agents. They work by decreasing the colonic concentration of ammoniogenic bacteria. Neomycin dosing is 250-1000 mg orally 2-4 times daily. Treatment with neomycin may be complicated by ototoxicity and nephrotoxicity. Rifaximin (Xifaxan) is a nonabsorbable antibiotic that received FDA approval in 2004 for the treatment of travelers' diarrhea and was given approval in 2010 for the reduction of recurrent hepatic encephalopathy. This drug was also approved in May 2015 for the treatment of diarrhea-predominant irritable bowel syndrome (IBS-D). Data from Europe suggest that rifaximin can decrease colonic levels of ammoniogenic bacteria, with resulting improvement in the symptoms of hepatic encephalopathy.

- Ascites - treatment can include sodium restriction and the use of diuretics, large-volume paracentesis, and shunts (peritoneovenous, portosystemic, transjugular intrahepatic portosystemic).

Spirolactone (Aldactone) blocks the aldosterone receptor at the distal tubule. It is dosed at 50-300 mg once daily. Although the drug has a relatively short half-life, its blockade of the aldosterone receptor lasts for at least 24 hours. Adverse effects of spironolactone include hyperkalemia, gynecomastia, and lactation. Other potassium-sparing diuretics, including amiloride and triamterene, may be used as alternative agents, especially in patients complaining of gynecomastia.

Furosemide (Lasix) may be used as a solo agent or in combination with spironolactone. The drug blocks sodium reuptake in the loop of Henle. It is dosed at 40-240 mg daily in 1-2 divided doses. Patients infrequently need potassium repletion when furosemide is dosed in combination with spironolactone.

Aggressive diuretic therapy in hospitalized patients with massive ascites can safely induce a weight loss of 0.5-1kg daily, provided that patients undergo careful monitoring of renal function. Diuretic therapy should be held in the event of electrolyte disturbances, azotemia, or induction of hepatic encephalopathy.

Vasopressin V2 receptor antagonists are a class of agents with the potential to increase free-water excretion, improve diuresis, and decrease the need for paracentesis.

- Vitamin K and a blood plasma can be given in emergencies to treat episodes of bleeding.

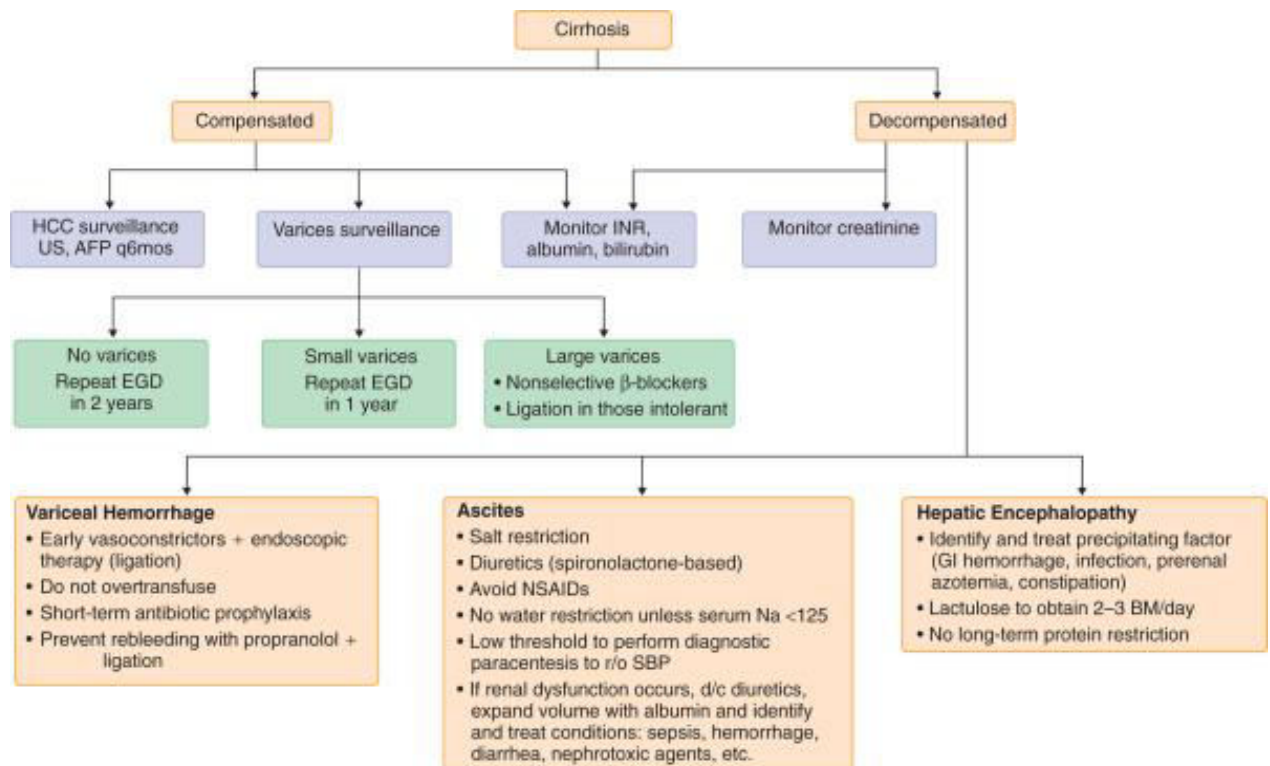
Nonselective beta-blockers (propranolol, nadolol) reduce portal pressures and are used in the primary and secondary prophylaxis of variceal hemorrhage. β -adrenergic blockers reduce portal pressure by producing splanchnic vasoconstriction and decreasing portal venous inflow. Propranolol is initiated at a dose of 20 mg orally twice a day, whereas nadolol is initiated at a dose of 20 mg orally every day. The dose should be titrated to produce a resting heart rate of about 50 to 55 beats per minute. In patients who have early cirrhosis without moderate-to-large varices, beta-blockers do not prevent the development of varices and also result in adverse effects. The clinical window opens when moderate-to-large esophageal varices develop, with or without variceal bleeding, and beta-blockers are indicated for primary and secondary prophylaxis of variceal bleeding. Increasingly, evidence suggests that the clinical window for beta-blockers closes and that they are no longer effective when refractory ascites, hypotension, the hepatorenal syndrome, spontaneous bacterial peritonitis, sepsis, or severe alcoholic hepatitis develops, owing to unfavorable hemodynamic effects in advanced cirrhosis.

The use of invasive measurement of the hepatic venous pressure gradient to guide beta-blocker use may predict clinical efficacy and provide useful prognostic information.

Although the role of beta-blockers in patients with end-stage cirrhosis remains controversial, there is increasing awareness of the role of blood pressure in the survival of patients with cirrhosis. The most recent Baveno VI consensus guidelines regarding portal hypertension recommend the discontinuation of beta-blockers when the systolic blood pressure is less than 90 mm Hg, the serum sodium concentration is less than 120 mmol per liter, or acute kidney injury has developed. Our practice is to discontinue beta-blockers when the systolic blood pressure is less than 100 mm Hg, because a blood pressure of 100/73 mm Hg is required to obtain the mean arterial pressure of 82 mm Hg that has been described to correlate with survival.

Analgesic agents must be carefully selected in patients with cirrhosis. Because of the risk of acute renal failure and gastrointestinal bleeding, nonsteroidal antiinflammatory drugs are contraindicated, except for low-dose aspirin in patients in whom the severity of cardiovascular disease exceeds the severity of cirrhosis. Opiates should be used cautiously or avoided, because they may precipitate or aggravate hepatic encephalopathy. Tramadol is safe in low doses, and topical medications such as lidocaine patches are generally safe. Acetaminophen is effective and safe in patients with liver disease, provided that the patient does not drink alcohol.

Patients should be referred for consideration for liver transplantation after the first signs of hepatic decompensation.



AFP = α -fetoprotein; BM = bowel movement; d/c = discontinue; EGD = esophagogastroduodenoscopy; GI = gastrointestinal; HCC = hepatocellular carcinoma; INR = international normalized ratio; Na = sodium; NSAIDs = nonsteroidal anti-inflammatory drugs; r/o = rule out; SBP = spontaneous bacterial peritonitis; US = ultrasound.

Materials for self-control:

Situation tasks:

1. A patient, 54 years old, complains of general weakness, absence of appetite, dull pain in the right subcostum, abdominal bloating, weight loss. Lately periodic vomiting with blood appeared. Examination: body weight is reduced, icterus of scleras, skin is dry, "vascular stars" on face and upper extremities, hyperemia of hands, gynecomastia. Tongue is of raspberry colour. Abdomen is enlarged, lower edge of liver is acute, dense, comes from the edge of costal arc on 4 cm. Spleen comes from a costal arc on 6-7 cm. Blood sedimentation is 14 mm/h, thymol test – 8. What is the preliminary diagnosis? What additional tests are necessary?
2. Patient was confirmed micronodular liver cirrhosis. During last 2 months he noticed the development of dyspnea, edemas of lower extremities, ascites. Patient was taking hepatoprotectors and glucocorticoids. What combination of medicines should be added to the treatment, which is already conducted?
3. A woman, 42 years old, is suffering from micronodular cryptogenic hepatic cirrhosis. During the last week state worsened: cramps and dizzinesses appeared, memory had worsened, icterus increased. What complication developed? What research can explain the reason of worsening?

Tests:

1. A patient with hepatic cirrhosis drank some spirits that resulted in headache, vomiting, aversion to food, insomnia, jaundice, fetor hepaticus, abdominal swelling. What complication of hepatic cirrhosis is meant?

- A. Hepatocellular insufficiency
- B. Hemorrhage from varicosely dilatated veins of esophagus
- C. Portal hypertension
- D. Acute stomach ulcer
- E. Thrombosis of mesenteric vessels

2. In which of the following disorders does the pathophysiology of portal hypertension involve presinusoidal intrahepatic obstruction?

- A. Alcoholic cirrhosis
- B. Congenital hepatic fibrosis
- C. Hemochromatosis
- D. Budd-Chiari syndrome
- E. Cavernomatous transformation of the portal vein

3. A 42-year-old female patient suffers from micronodular cryptogenic cirrhosis. Over the last week her condition has deteriorated: she developed convulsions, mental confusion, progressing jaundice. What study may give reasons for such aggravation?

- A. Determination of serum ammonia
- B. Determination of cholesterol ethers
- C. Determination of alpha-phetoprotein
- D. Determination of ALAT and ASAT
- E. Determination of alkaline phosphatase

4. Patient K., 24 years old, complains of pain in the right subcostum and joints, icteric skin, weight loss - 10 kg for a year, temperature 38°C. A disease began after childbirth half a year ago. Objectively: icteric skin and scleras, there are xanthomas on eyelids. Liver +4 cm, dense, painful, edge is sharp. Spleen +2 cm. Blood tests: AST - 2,8, ALT - 3,4, general bilirubin - 97,6, free - 54,6, HbsAg was not determined. Name the basic mechanism of pathogenesis:

- A. Viral infection
- B. Toxic damage of hepatocytes
- C. Fatty dystrophy of liver
- D. Violation of bile outflow
- E. Autoimmune

5. A man, 40 years old, suffers from autoimmune hepatitis. In blood: general bilirubin 42 mkmol/l, transaminases: ALT - 2,3, AST - 1,8. What is the most effective treatment?

- A. Glucocorticoids, cytostatic preparations
- B. Antibacterial preparations
- C. Hepatoprotectors
- D. Antiviral preparations
- E. Hemosorbction, vitamin therapy

6. Patient, 49 years old, complains of general weakness, increased ascites during 2 months. After the abdominal puncture 10l of pale yellow transparent liquid was got. Painless liver is palpated with acute even edge, it comes under a costal arc on 4 cm and spleen is 2 cm

below an edge of costal arc. The syndrome of cytolytic is absent. Roentgenologically stomach and duodenum have no changes. What disease is it possible to think about?

- A. Pick`s pseudocirrhosis
- B. Cryptogenic micronodular hepatic cirrhosis
- C. Chronic toxic hepatitis
- D. Biliary hepatic cirrhosis
- E. Phlebitis of hepatic vein (Budd – Chiari disease)

7. 49 years old man, invalid of the I group, treats concerning the hepatic cirrhosis during a few years. For the last months abdomen increased in size, weakness intensified. He took furosemide daily for 2 weeks. What blood changes of electrolytes do you expect to find out?

- A. Hypokaliemia
- B. Hypocalciemia
- C. Hypernatriemia
- D. Hypercalciemia
- E. Hyperkaliemia

8. A man, 46 years old, complains of vomiting with bright red blood. In the anamnesis: micronodular hepatic cirrhosis of viral etiology for 5 years. During last half year increasing abdominal size due to ascites was observed. What preparation is it necessary to begin with?

- A. Cordiamin - 2 ml intramuscular
- B. Intravenous vasopressin - 20 units
- C. Mesaton 1% - 2 ml intramuscular
- D. Prednizolon - 20 mg intravenous
- E. Swallowing of ice pieces

9. Patient I., 50 years old, was got to hospital in extremely hard condition. At the examination: common sense is absent, skin and scleras are icteric. Liver is enlarged, splenomegaly. Ascites is determined, acidic breathing, tachycardia, AP 90/40. There are subdermal hematomas, erythemas of hands. Metabolic hyperacidity: pH - 7,1, AST - 1,8, ALT - 2,1. General bilirubin of blood - 334,2 mkmol/l, sodium of blood serum - 122 mmol/l, potassium of blood serum - 5,9 mmol/l. Worsening of patient`s condition is associated with:

- A. Thrombosis of mesenterial vessels
- B. Poisoning with alcohol substitutes
- C. Heart failure, III stage
- D. Violation of cerebral blood circulation
- E. Hepatic coma

10. A patient, 44 years old, abuses alcohol for a long time. Objectively: thenar and hypothenar are red, vascular stars on the front surface of thorax, veins of anterior abdominal wall are dilated. Abdomen is bloated, free liquid is determined in abdominal cavity. Liver + 4 cm, smooth, unpainful. The edge of spleen is palpated. In blood: L - $8,7 \times 10^9/l$. What complication developed?

- A. Subacute hepatic dystrophy
- B. Portal hypertension
- C. Coagulopathy

- D. Thrombosis of mesenteries vessels
- E. Hypersplenism

Correct answers for the situation tasks:

1. Liver cirrhosis. Biochemical blood analysis (liver tests), markers of hepatitis in serum, US of abdominal cavity, liver biopsy if necessary.
2. Diuretics (spironolactone, furosemide).
3. Hepatic encephalopathy. Determination of ammonia in blood serum.

The answers for the tests:

1-A, 2-B, 3-A, 4-E, 5-A, 6-B, 7-A, 8-B, 9-E, 10-C.

Recommended literature:

1. Goldman's Cecil medicine / [edited by] Lee Goldman, Andrew I. Schafer. – 24th ed. USA 2012, Elsevier p. 2569
2. Harrison's Principles of Internal Medicine / D.Kasper, A.Fauci, S.Hauser, D. Longo.-19 ed. – N.Y.: McGraw-Hill Professional, 2015. - Vol. 1, Vol.2. - 3000 p.
3. <http://emedicine.medscape.com/article/185856-overview>

Composed by Radionova T. O.