

THE MINISTRY OF HEALTH OF UKRAINE  
THE HIGHER STATE EDUCATIONAL INSTITUTION OF UKRAINE  
"UKRAINIAN MEDICAL STOMATOLOGICAL ACADEMY"

Approved at the meeting of orthodontics  
protocol № 1 by 23.08.2017 y.

Head of department\_\_\_\_\_L.V. Smaglyuk

**METHODICAL RECOMMENDATION**  
**for independent work of students during the preparation**  
**to practical lessons and on the lessons**

Academic discipline	Orthodontics
Module № 2	Anomalies and deformation of denta- jaw region
The theme of the lesson № 3	Dental arches anomalies
Course	IV
Faculty	Preparation of foreign students

Poltava 2017

**1. The relevance of the topic.** Knowledge of the etiological factors and pathogenesis of the development of dental arches forms anomalies is necessary for the preparation of the diagnosis, the choice of the most rational method of treatment, which will lead to a stable treatment result .

**2. Specific objectives:**

To study the groups of factors that lead to the development of dental arches forms anomalies.

To determine the factors that lead to the development of dental arches forms anomalies in the process of growth and development of the dento-alveolar system of human.

**3. Basic knowledge's, abilities, skills necessary for studying the topic (interdisciplinary integration)**

Name of previous disciplines	Skills
1. Anatomy	to know features of the structure of individual teeth and jaws.
Pathological physiology	mechanisms of development of maxillofacial system deformations under the influence of different etiological factors
3. Medical biology	the mechanisms of inheritance pathology of individual teeth.

**4. Tasks for independent work during preparation to the lesson and on the lesson**

4.1.A list of the main terms, parameters, characteristics that need to learn by the student during the preparation to the lesson:

Terms	Definition
1. Narrowed dentition	There is compression of the dentition along the entire length with the front portion extended forward (the front teeth are closely or fan-shaped)
2. Saddle-shaped dentition	There is an uneven narrowing of the dentition and a particularly pronounced compression (compression) in the region of premolars and molars of both sides
3. V- shaped dentition	Characterized by a sharp narrowing and protruding forward of the frontal area to the formation of an acute angle (the front teeth are most often closely located)
4. Trapezoid dentition	When the front part of the dental arch is flattened and the whole dentition has the form of a trapezoid
5. Asymmetric dentition	Characterized by uneven development of both halves of the jaw

#### 4.2. Theoretical questions to the lesson:

1. The main etiological factors that contribute to the development of anomalies of dental arches in the antenatal period.
2. Factors that lead to the development of anomalies of dental arches in the postnatal period.
3. Classification of abnormalities of dental arches (anomalies of the form of dentition) by D.A. Kalvelis.
4. Risk groups for the development of abnormalities of dental arches.
5. Characterize the anomalies of the dentition in the transversal plane.
6. Extended dentition features of diagnosis and treatment.
7. Narrowed dentition features of diagnosis and treatment.
8. Anomalies of dentition in the sagittal plane.
9. Anomalies of dentition in the vertical plane.
10. Forecasting the development of abnormalities of dental arches.

#### 4.3. Practical works (task) which are executed at the lesson:

- determination of risk factors of development of individual teeth anomalies.
- definition of pathogenesis of individual teeth anomalies.
- determining the risk of development of individual teeth anomalies.
- definition of forecast of occurrence of individual teeth anomalies.

#### **The content of the topic:**

When the diagnosis of "Anomalies of dental arches" is used, the D.A. Kalvelis classification is used, according to which the following disorders are distinguished: a) narrowed dentition; b) saddle-shaped compressed dentition; c) the V-shaped form of the dentition; d) quadrangular dentition; e) asymmetric.

In relation to the three mutually perpendicular planes, the following anomalous forms of the dentition are distinguished:

- in the transversal direction – narrowing and widening of the dentition,
- in the sagittal – elongation and shortening of the dentition,
- in the vertical – dental alveolar shortening and dental alveolar elongation in individual segments of the dentition.

#### Anomalies of dentition in the transversal plane.

Anomalous forms of dentition in the transversal plane are distinguished as follows: 1) V-shaped, when the dentition is narrowed in the lateral sections, rotation of the central and sometimes lateral incisors around the longitudinal axis and the protruding front portion; 2) trapezoid, when the dentition in the lateral sections is narrowed, and the anterior one is flattened; 3) the common narrowed dentition, when both the front and side teeth are located to the median plane than it should be in the norm; 4) saddle shape, when the narrowing is most pronounced in the region of the second premolar and the first molar; 5) asymmetric shape, when the location of the lateral teeth to the median plane of one and the other side is

different, 6) the anomalies of the dentition in the presence of several supernumerary teeth.

Narrowed dentition. The narrowed teeth rows are characterized by a change in their shape due to a decrease in the distance between the median plane and laterally located teeth.

The narrowing of the upper dentition is determined with respect to the mid-sagittal suture, the lower one with respect to the median plane of the face and jaw.

The main etiological factors of the narrowing of the dentition, the alveolar arch and the apical base are:

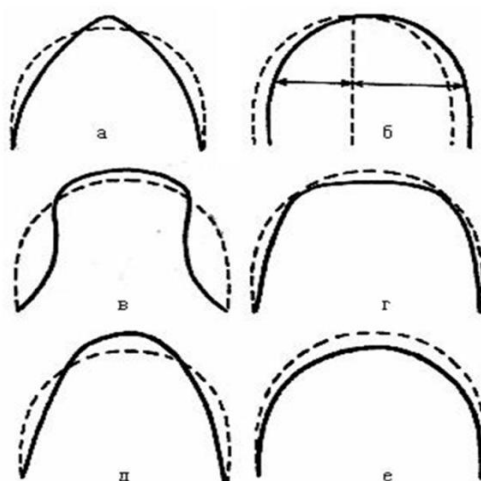
- 1) difficulty nasal breathing, primary breathing through the mouth;
- 2) thumb sucking, several fingers or another objects;
- 3) violation of the function of swallowing, speech;
- 4) parafunction of mimic and chewing muscles and muscles of the tongue.

The narrowing of the dentition and the lack of space for the front teeth can be explained by the weak pressure on the teeth of the inactive tongue with its short frenulum and the prevalent action of the muscles of the lips and cheeks.

Lazy chewing or chewing food on one side does not have a stimulating effect on the growth of the jaw bones and is one of the etiological factors of narrowing the dentition. The narrowed dentition in turn complicates lateral chewing movements of the lower jaw and forms a "vicious circle", aggravating the anomaly of development and formation of both dentition and bite.

Premature loss of temporary teeth, especially molars, significantly reduces masticatory pressure, which is one of the main factors stimulating the physiological and proportional development of the jaw bones, which also causes their narrowing.

Common diseases of the body – rickets, dyspepsia, infectious and other diseases that affect the metabolism, weaken the body and can cause a narrowing of the dentition.



Narrowing of dentition can often be a symptom of almost all bite anomalies. It is accepted to distinguish the narrowing of the dental, alveolar and basal arches, which is revealed on the control and diagnostic models of the jaws.

The narrowing of the dentition can be one-sided or bilateral, symmetrical or asymmetrical, on one or both jaws, without disturbing the closing of the dentition

and with violation. There is a narrowing of the dentition with protrusion of the front teeth without three between them, with protrusion of the front teeth and a crowded position, with protrusion of the front teeth and the presence of diastems and three between them. Of all the above variants, the crowded position of the front teeth is more often observed with the rotation of some teeth around the longitudinal axis, partial or complete retention of individual teeth.

Diagnosis is established on the basis of clinical and radiological examination, as well as the study of control and diagnostic models of the jaws. Determine the width of the dentition in the premolar and molar region using the Pont method with the Linder-Hart correction, the Snagina method, and the width of the apical base (according to Howes). Comparison of the obtained data with the individual norm allows one to determine the severity of the dentition and choose a rational method of treatment.

In this case, take into account: 1) the closing of the lateral teeth (1, 2 and 3 of Engle's class); 2) narrowing of the dental arch, alveolar, basal; 3) the position of the lateral teeth, i.e. Whether the dull position of the front teeth is due to underdevelopment of the jawbone basis or other causes; 4) whether the active period of growth of jaws has come to the end; 5) whether the anomaly can be eliminated by the orthodontic method or preliminary compactosteotomy (surgical-orthodontic method), or only surgical method is required.

Treatment consists in the expansion of the dentition and their apical basis, the determination of possible options for setting individual teeth in the correct position, determining orthodontic indications for removing less valuable functional and aesthetically pleasing teeth to create a place in the dentition or to determine the extent of other surgical procedures (plastic frenulum ore tongue, compactosteotomy, etc.).

Expansion of the dentition is achieved with the help of various designs of removable and non-removable orthodontic devices.

*Removable plate expansive orthodontic devices.* One of the first orthodontic devices for expanding the dentition was proposed in 1882 Coffin – a plate-type apparatus with a wire spring located at the center of the base and sagittal cut. In 1886, Kingslej in the basis of the orthodontic apparatus put the screw. Schwartz improved the expanding plates, adding to them arrow-shaped clasps, retractive arcs, various springs and devices for moving teeth. Kalvelis D.A. Modified Coffin's expanding coil spring.

More commonly used removable plate machine with a screw for uniform expansion of the dentition, the basis of which is placed an expanding screw.


Skeletonized (large and small) screws with a closed body are used in a permanent bite for the expansive opening of the median palatine suture.

The largest narrowing of the dentition is usually observed in the premolar region, so when the sagittal base plate of the plate apparatus the screw is installed between the premolars. The distance between the model and the screw should be 0.5-0.7 mm. The sawing of the basis is oriented on the position of the central incisors, on the base of the frenulum of the tongue and the place of attachment of

the bridle lips. A plate apparatus with a vestibular arch and an expanding screw is used to simultaneously expand and shorten the dentition.

Asymmetric expansion of the dentition is achieved by means of plate-shaped apparatus with a screw and shaped sectoral cuts. In the region of the lateral teeth subject to vestibular displacement, the dentition is disunited.

To this end, the occlusal patches on the lateral teeth with the imprints of the chewing surface of the lower teeth are made on the opposite side. For uneven expansion of the upper dentition, larger in the front and smaller in the lateral, special screws are used. When they expand, both halves of the base diverge in a fanlike manner, which is achieved with a screw with a restrictive hinge located in the distal portion of the upper jaw plate, in addition, the uneven expansion of the upper dentition is achieved by a plate orthodontic device with a single or double Coffin spring or with a clasp spring, As well as with the screw and sectoral sawing of the basis.



The design of the expansive plate apparatus for the lower jaw with a significant narrowing of the dentition and lingual tilt of the lateral teeth has some peculiarities. The lower edges of the basis of the apparatus must be thickened, since during pre-pressing, it is necessary to cut the plastic from the inner surface.

In order to better fix the plate machine and prevent its slipping towards the bottom of the oral cavity, it is recommended to wire the occlusal overlays on the lateral teeth. The screw should be untwisted weekly for  $\frac{1}{4}$ - $\frac{1}{2}$  turns (1-2 movements). Instead of a screw to expand the dentition, you can apply a co-ax of Koffin – single or double.

A plate with two Koffin springs serves to uniformly widen the upper tooth row. Springs are bent from an orthodontic wire with a diameter of 0.6 to 0.8 mm, the ends are zigzag-shaped to ensure their secure fixation in a plastic base. When the finished apparatus is inserted into the oral cavity, the springs are compressed. They tend to straighten and transmit pressure to the teeth through the basis of the apparatus. The springs are activated by extension.

Actively acting element of the expanding platelet apparatus for the lower jaw is an orthodontic screw or a spring with additional semicircular bends. Use also the standard springs of the Koller with a W-shaped loop width of 30-35 mm.

When manufacturing the bugle, the springs are not covered with plastic, it is under the lower edge of the basis, deviating 0.5 mm from it. To expand the dental rows, in addition to removable mechanically - and functionally operating orthodontic devices and devices used and non-removable.

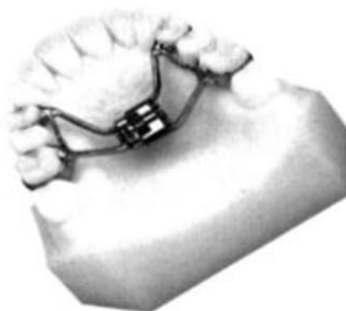From non-removable devices for the expansion of dental rows, the apparatus of Ainsworth, the Simon beam apparatus, the Angl's spring apparatus, the Begg-technique, the lingual arc by Mershon, Gerbst, with auxiliary spring ends are used. Appliances by Nord, Derihsvailer, Bruna for accelerated opening of the median palatal steach, Levkovich's kap, apparatus with removable expanding springs, etc.

The lingual arch by Mershon is fixed with the help of special locks soldered on the palatal surface of the crowns or rings on the first permanent molars. It expands the dentition in the area of molars and premolars.

V-shaped Gerbst lingual arch is fixed from the oral surface of the crowns of the first molars and is able to expand the dentition in the region of molars, premolars and canines.

In the period of permanent bite, depending on the severity of the narrowed dentition and the apical base, one of the following methods is chosen:

1. When the dentition or dental alveolar arch is narrowed to 5 mm, in comparison with the individual norm, orthodontic treatment with the use of plate devices with screws or springs of Coffin, Kalvelis or non-removable arc devices is shown.
2. With a narrowing of the tooth or dental alveolar arc by more than 5 mm compared with the individual norm, combined treatment is indicated - preliminary surgical preparation in the form of compactosteotomy or tooth extraction (teeth) and subsequent orthodontic treatment.
3. When the apical basis of the maxilla is narrowed, equal to 37% or more in comparison with the individual norm (according to Howes), a combined treatment is performed - removal of individual teeth, compactosteotomy and subsequent orthodontic treatment. In severe forms of constriction, the median palatine suture is opened by means of non-removable dilating orthodontic devices.



The first group consists of machines proposed by Stenton, Schroder-Bousler, Nord, Levkovich, and others. These are rings or crowns fixed on the lateral teeth, connected together by a cast intermediate piece and a screw.

Among the first designs of devices designed to open the palatine seam are the apparatus of Nord, the kappa apparatus with the Brun screw, the Levkovich's kapas apparatus with the Coffin spring, etc. The supporting part of such apparatuses are rings or crowns for the second premolars and molars to which, from the palatine surface Soldered rods adjacent to the first premolars and canines,

transmitting pressure on these teeth during the unwinding of the expanding screw. When using this device, all the load is transferred to the supporting teeth, which can lead to overload of the teeth.

The second group is the apparatus proposed by Derichsweiler, Chateau, Khoroshilkina, etc. These are rings or crowns fixed on the first premolars and molars, connected together by a cast or wire fittings, with a screw and a plastic basis resting on the alveolar process.

When the screw is unscrewed, its pressure is transferred to the alveolar process, the lateral teeth, which not only provides a more equal distribution of the screw force to the teeth and alveolar process, but also to the change in the shape of the hard palate.

#### Extended dentition.

Extended dentition is characterized by an increase in the distance between the median plane and laterally located teeth. The main etiological factors of the dilated dentition and their apical basis are as follows:

1) With dental alveolar forms – abnormal laying of the follicles of the teeth, bad habits, parafunction of the muscles of the maxillofacial region, delay in physiological dentition;

2) With gnathic forms – macrognathia hereditary or acquired, tumors, etc.

An enlarged dental arch is observed with neutral, distal or medial occlusion of the lateral teeth and vertical occlusion abnormalities. It is much less common than narrowed. The enlarged dental arch can be a one-sided violation, bilateral, symmetrical, asymmetric, on one jaw, on both jaws, without disturbing the closing of the dentition or with impairment.

Treatment can be applied orthodontic or in combination with surgical. For the correction of the shape of the dental arch, more often mechanically - the acting single-jaw arc Engels, the bracket-technique or the rings of the jagged arches of the upper and lower jaws with inter-maxillary traction are used more often. On the expansion side, the arcs are bent so that it exerts pressure on the supporting and moving arcs in the oral direction.

To narrow the upper dentition a non-removable skeleton is used. It consists of supporting rings on the upper lateral teeth (usually the first premolars and molars). From the vestibular side, they are soldered to the rods touching the crowns of the upper lateral teeth and transferring pressure to them in the oral direction. From the palatal side to the crowns solder 3 - 4 pieces of flattened wire diameter of 1,2 mm along the midline of the sky, untwisted orthodontic screw. The metal elements of the apparatus must be 1 to 3 mm from the sky. The apparatus is strengthened on the teeth with the help of Phosphate cement or Wisfat cement.

A day later, the screw is twisted (twisting), which leads to the oral (to the median – sagittal plane) dento-alveolar movement of the lateral fragments of the dentition.

In the case of the use of functionally active devices, for example, the Frenkel function regulator, on the side of the tooth-alveolar widening, the side shield should be adjacent to the teeth and to the alveolar process. When the transversal



contacts between the dentition are broken, the treatment corresponds to the principle of treating the cross bite.

### **Anomalies of dentition in the sagittal plane**

**Extended dentition.** Elongated dentition is determined by their total length and the length of their anterior segment. The causes of such anomalies can be: 1) violations of functions – nasal breathing, swallowing (the surviving infantile type of swallowing), articulation of the language during the function of speech; 2) violations of motor reactions – sucking fingers, tongue, lips and other foreign objects; 3) anatomical predisposition - the presence in the dentition of one or more supercomplete teeth, preserved temporary teeth in the presence of all the complete teeth, the presence of diastems and "three primates", etc.

In most cases, the front teeth protrude from under the lips and there are no contacts between them, a sagittal slot of different sizes is formed depending on the etiological factor and the duration of its effect.

At a younger age, during a temporary bite, the elimination of bad habits, the normalization of the functions of the dentoalveolar system contribute to self-regulation of the abnormalities. Vestibular plates (Schoncher's plate), regulators of Frenkel's function, Andrezen's activator-Goiple, an open activator of Clamt, etc. can be used according to indications.

During the period of the replaceable and permanent bite, in addition to the listed measures, orthodontic devices with various kinds of tooth arches are used to retract the front teeth, according to the indications, separate teeth are removed. To shorten the dentition, mechanically acting orthodontic devices with inter-maxillary and extra-oral traction, a removable plate apparatus with an expanding screw and a vestibular arch, fixed on the molars by Adams or Schwarz clasps are used.

A good therapeutic result is achieved by the use of non-removable arc devices, including bracket-techniques. The protrusion of the teeth is removed by an arc with closed loops. On the opposite jaw, it is possible to strengthen the oral (ligual) arch, connected with the supporting crowns or rings on molars, on the vestibular surface of which the hooks are soldered to fix the rubber rings providing the inter-maxillary traction.

**Shortened dentition.** The shortened dentition is determined by their total length and the length of their front portion. The shortening of the dentition may be the result of anomalies in the shape, size, number and location of the teeth, underdevelopment of the jaw, bad habits of sucking or biting the lips, tongue or any other foreign objects. The shortening of the dentition due to the medial displacement of the premolars and molars can be due to several reasons: 1) carious destruction of the proximal surfaces of the tooth crowns, 2) early loss of temporary or permanent teeth, 3) partial adentia, 4) retention of the teeth, 5) improper placement of the rudiments of permanent teeth Or by their eruption outside the dental arch.

Often there is a dull position of the teeth, the displacement of individual teeth from the dentition, more often in the oral direction, the retention of some teeth (often canines and second premolars). The violation can be one-sided or two-

sided. It is noted that the lip is lingering, with a deep incisive overlapping - a shortening of the lower third of the face. The truncated lower dentition is often observed with distal occlusion, the shortened upper dentition – with the mesial.

For the purpose of treatment, removable orthodontic devices are used: Schwartz plate machines with screws, springs, lingual arcs and other devices, as well as sectoral cuts.

When the screw is untwisted in the plate with the sectoral cut, the incisors and the distal displacement of the lateral teeth occur under the influence of the plastic bases, clamps and other devices adjacent to them. The long axis of the screw is installed in the direction of movement of the teeth. The saw is produced at the level of the middle of the canine crowns. When sawing a sector in plastic, equal to the width of the crowns of the displaced teeth, it is important to make sure that the sides of the saw are parallel - this prevents wedging of the moving sector when the screw is unscrewed. With a direct and open bite, the oral surface of the moving upper anterior teeth is covered with plastic. With the reverse incisal overlap, the front teeth are separated with the help of occlusal lining from the plastic on the lateral teeth. The sectoral cut in the posterior – lateral region allows, with sufficient support of the apparatus, to move the lateral teeth in the distal direction, as well as in the distal - vestibular, oral, which depends on the location of the longitudinal axis of the screw. Movement of the lateral teeth in the distal direction, i.e. Toward the wider part of the dental arch, contributes not only to elongation, but also to the widening of the upper dentition.

To elongate the dentition due to the distal displacement of the lateral teeth, a plate apparatus with two screws is made. They are located, according to indications, between the canines and the first premolars, between the premolars or between the second premolar and the first molar, depending on the specific situation. After sawing the basis of the apparatus, a large support sector is formed for the front teeth and two sectors of smaller size for the lateral teeth.

This design of the orthodontic apparatus can be carried out as a uniform on both sides, as well as uneven extension of the dentition. It is recommended to activate the screws of the machine screws not simultaneously, but alternately, with a break in two days. This activation mode retains the condition of a larger area of the fulcrum and lesser – the point of application of the force, which vary among themselves depending on the alternation of the activation period of each screw.

The extension of the dentition is also achieved by the use of functionally active devices (the Andresen-Hoypl activator, the Frenkel function regulator, etc.) that stimulate the growth of the jaw in the sagittal direction. These apparatuses are attached screws, potholes, levers and other devices to affect individual teeth or groups of teeth.

In addition to removable single and double-jaw apparatus for the extension of the dentition, the non-removable devices of Krosat, Gerling-Gashimov, Kalamkarov, and others are used.

For the distal movement of canines, premolars and molars, ejouaise is a technique in combination with teeth spreading the teeth, as well as inter-maxillary

traction. If the removal of individual teeth is shown, then after the last one it is possible to complete the treatment with bracket – system.

Effective combined non-removable device, consisting of rings for the first premolars and the first molars of the upper jaw with locks, sectoral arcs and tension springs, worn on these arcs. To the palatal surface of the rings, the first premolars are soldered with wire segments, the ends of which are placed in a tooth-alveolar pelot adjacent to the palatal surface of the incisors. On the pelot, a bite pad is made for the incisors of the lower jaw. The force of the action of the tension springs ensures the distal movement of the molars and the vestibular movement of the incisors.

In recent years, non-removable arc devices have been used to fix braces from the palatal surface of the tooth crowns. With the same purpose, special braces are offered. Such devices perform all the necessary functions, but they have significant advantages from an aesthetic point of view, since they are invisible to others.

For bilateral distal movement of the upper lateral teeth, a facial arch with an extra-oral support on the occiput or on the neck is often used. The distal movement of premolars and molars with a constant bite (after the end of the period of active growth of the jaw bones) presents considerable difficulties, in such cases the removal of individual teeth can be a method of choice.

### **Materials for self-control:**

A. Tasks for self-control (tables, diagrams, drawings, graphs):

- to sketch in the album the scheme of dental arches form anomalies.
- to sketch in the album appliances for dental arches form anomalies treatment.

B. Tasks for self-control:

1. A group of dental arches form anomalies are presented in the classification:

D. A. Kalvelis

A. Y. Katz

A. I. Betelman

L. V. Illinois-Markosian

L. P. Grigorieva

2. Determine the dentition anomaly in transversal direction:

narrowing

intrusion

extension

dento-alveolar lengthening

dento-alveolar shortening

3. Determine the anomaly of dentition in the sagittal direction:

shortening

narrowing

expansion  
dentoalveolar lengthening  
dentoalveolar shortening

4. Determine the dentition anomaly in the vertical direction:

dento-alveolar shortening  
shortening  
narrowing  
expansion  
dento-alveolar increasing

5. Which of the following events does not affect the shape of the dental arch?

the oral cavity sanitation  
normalization functions of chewing, swallowing, breathing  
elimination of harmful habits  
upper lip frenulum plastic surgery  
tongue frenulum plastic surgery

6. Which can lead to the formation of an asymmetric narrowing of the dentition?

premature loss of temporary molars on one side  
tongue-tied  
lazy chewing  
sucking thumb  
infantile type of swallowing

7. What kind of pathological forms may have dentition in children with shortened tongue frenulum?

flattened  
V-shaped  
asymmetric  
triangular  
saddle-shaped

8. Which leads to symmetric narrowing of the dental arches?

lazy chewing  
mouth type of breathing  
shortened tongue frenulum  
thumb sucking  
dysfunction of the swallowing, speech

9. For the treatment of some dental anomalies used vestibular shields?

narrowing of the upper dental arch with the frontal teeth protrusion  
deep bite  
open bite

dysfunction of the swallowing, speech  
vestibular location of canines

10. What kind of pathological dentitions form at the mouth type of breathing?

U-shaped  
saddle-shaped  
sharp-shaped  
trapezoid  
asymmetric

11. What kind of pathological forms may have a dentition in children with a lazy chewing?

general narrowing  
saddle-shaped  
sharp-shaped  
trapezoid  
asymmetric

12. What reason leads to the expansion of the dental arch?

macroglossia  
sucking tongue  
thumb-sucking  
the mouth type of breathing  
microdontia

13. What etiological factors may contribute to the lengthening of the dental arches?

supernumerary teeth  
adentia  
unilateral chewing  
impacted teeth  
early loss of teeth

14. Which leads to a shortening of the dental arches?

partial adentia, impacted teeth  
the mouth type of breathing  
thumb-sucking  
incorrect tongue articulation  
macrodontia

15. For the treatment of asymmetrically narrowed dentition in the mixed dentition will need:

to deactivate the occlusion in the posterior teeth that are to be moved (from the opposite side to make lateral bite plane), asymmetric screw position  
to make the frontal bite plane

using protractive springs  
to make lateral bite planes in lateral areas  
there is no correct answer

## **Literature**

### **Main:**

1. Flis P.S. "Orthodontics". – Kyiv, MEDICINE, 2008, – 31-39p.
2. Golovko N.V. et al. Orthodontics. Occlusion development, diagnostic of malocclusion, orthodontical diagnosis. Poltava,– 2008, – 95p.

### **Additional:**

1. Pubmed. – Режим доступу: <http://www.ncbi.nlm.nih.gov/pubmed/>
2. Google Scholar – Режим доступу: <https://scholar.google.com.ua/>
3. BASE. – Режим доступу: <https://www.base-search.net/>
4. European Journal of Orthodontics. – Mode of access: <https://academic.oup.com/ejo>
5. Angle Orthodontist. – Mode of access: <http://www.angle.org/?code=angf-site>